

Special Article – End Colostomy

Uncut Diverting End Colostomy Technique and Its Results

Cakir M*

Department of General Surgery, Necmettin Erbakan University, Turkey

*Corresponding author: Murat Cakir, Necmettin Erbakan University, Meram Medical Faculty, Konya/Turkey

Received: October 11, 2019; Accepted: December 03, 2019; Published: December 10, 2019

Abstract

Purpose: Ostomy is anastomosis of the gastrointestinal tract to the anterior abdominal wall. Several surgical complications may develop during the closing of the end colostomy. We define a new end colostomy technique that minimizes surgical complications.

Methods: We use this technique in cases that require temporary full diversion. The distal colon segment is closed without impairing the segment where the ostomy is to be opened followed by the opening of ostomy.

Results: This technique was performed on 48 patients. No major complications developed in patients whose colostomies were opened and closed. The closure was done through an elliptic incision around the ostomy.

Conclusion: A relatively easy technique for performing and closing an end colostomy without laparotomy.

Keywords: End colostomy; Technique; Total; Diversion

Introduction

Ostomy is anastomosis of the gastrointestinal tract to the anterior abdominal wall [1]. To this end, large intestine and small intestine are used. Depending on the purpose of opening, ostomy may be permanent or temporary. Ostomies are classified according to the way they are anastomosed to the anterior abdominal wall. Ostomies can be loop or end in shape.

The most significant challenge faced in end colostomy is finding the distal end during its closure. During the closure of the ostomy figuring out the anatomy generally takes a long time and undesired intestinal organ injuries may occur [2,3]. Surgery is postponed needlessly for the decrease of intra-abdominal adhesion. Time intervals required for the closure of ostomy vary. The interval for closure in loop ostomy is approximately 6-10 weeks while it is 6 months or longer in end colostomy [4-6].

We define a new end colostomy technique that alleviates the challenges of this demanding surgical dissection and rules out the possibility of failure to close the colostomy due to complications.

Method

Forty-eight patients that presented for ostomy to our hospital between January 2015 and January 2018 were included in the study. Patients' files were reviewed retrospectively. Surgical consent forms were obtained from all the patients following anesthesia preparation. The criterion in the selection of patients was designated to be requirement for diverting ostomy. These were the cases of patients who had undergone rectovaginal fistula and perianal area surgery for the treatment of perianal injuries and severe perianal infections such as Fournier gangrene. This study used no patient information or protected health information and was exempt from Institutional Review Board approval.

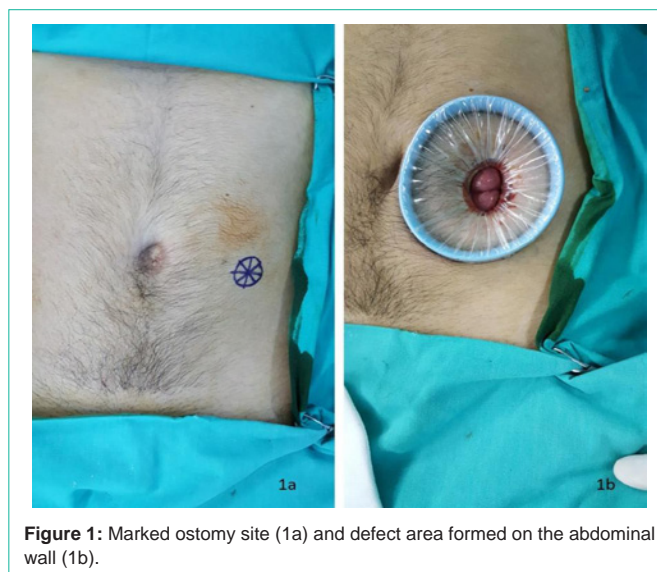


Figure 1: Marked ostomy site (1a) and defect area formed on the abdominal wall (1b).

All statistical analyses were performed on Statistical Package for the Social Science, Chicago, USA version 20. Data were expressed as mean \pm standard deviation.

Technique

A defect of 2-3 cm is formed in the previously marked ostomy site (Figures 1a,1b).

An Alexis wound protectors is fixed to this site. A glove or gel port is fixed onto the Alexis extractor and later trocars are placed (Figure 2).

Endoscopy tools are inserted into the trocar following insufflation. Sigmoid colon is laterally released by means of opening Toldt's fascia. The release is performed until it reaches the abdominal wall of the

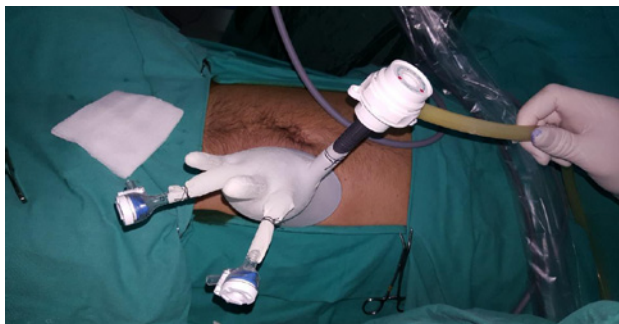

Figure 2: Placing of trocars.

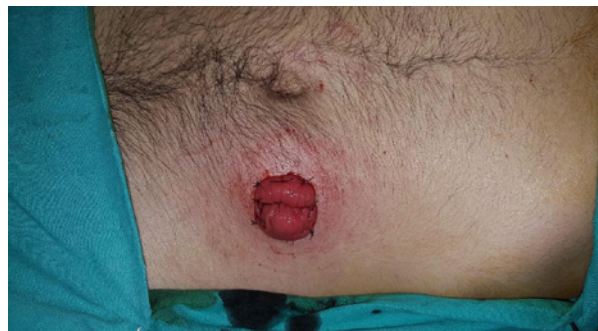

Figure 4: Maturation of ostomy.

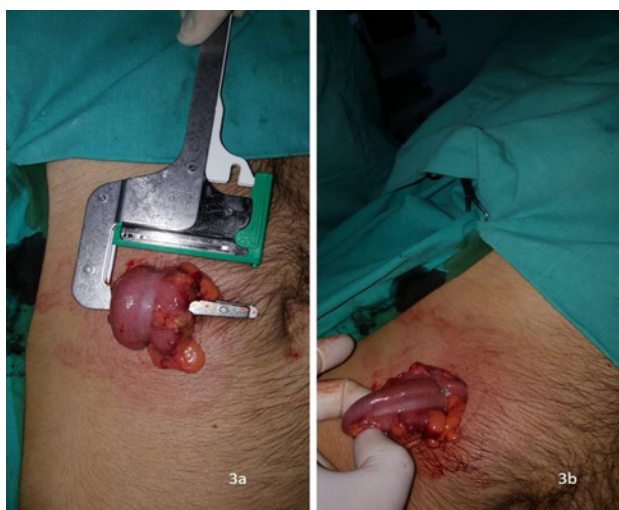

Figure 3: Placing of TA stapler (3a), Stapler line (3b).

colon segment.

The sigmoid mesocolon is medially released while aortomesenteric window remains unopened. The Alexis extractor is taken out and the intestinal segment is removed from the abdominal wall. A small defect is formed without cutting the distal end of the colon segment. The colon lumen is closed by means of a TA stapler (The DST Series™ TA™ Linear Stapler/ Medtronic /Minneapolis/ USA) placed through this section (Figures 3a,3b).

However, the colon integrity is not damaged. In other words, no incision procedure is performed. A loop colostomy is opened in the area 2-3 cm to the proximal of the closed intestinal segment. (Figure 4).

The 2-3 cm loop that remains in the distal can be easily drained from this area. The closed stapler line is as close to the ostomy site as possible. The short blind distal end facilitates the closing of ostomy. Thus, during the closing of colostomy only a very short colon loop is sacrificed. While the ostomy is being closed the closure is easily administered without having recourse to laparotomy or laparoscopy thanks to an elliptic incision around the ostomy. We approach the patients as if we were closing a loop ostomy.

Results

We have performed uncut end colostomy for forty-eight patients.

Table 1: Patients diagnoses.

Diagnosis	Gender		Total (n/%)
	Male	Female	
Perianal sepsis	8	15	23/48
Perianal injuries	6	1	7/15
Fecal incontinence	5	4	9/19
Rectovaginal fistula	0	4	4/8
Crohn's disease	4	1	5/10
Total	23	25	48/100

Table 2: Ostomy closure complications.

Closure complication	N	%
Bleeding	2	4,2
Minor leakage	2	4,2
Intraabdominal abscess	1	2,1
Wound site infection	4	8,3
Total	9	18,8

Of these patients, 23 (48%) were female and 25 (52%) were male. Their mean age was 50 (32-67). A great majority of the patients presented with uncontrolled perianal sepsis (Table 1).

The duration of surgery was 30 (15-60) minutes. It was seen that after 20 cases the duration of surgery dramatically shortened (P <0.05). No surgical complications occurred during the opening of ostomy.

All the patients' colostomies were closed. The average duration of closure 4 (1-10) months. Dehiscence was observed in stapler line of 1 patient. No complications occurred in patients whose colostomies were closed. Because the distance between the distal end and the ostomy opening in the first 3 patients we operated on was longer than 10 cm we kept the incision on the ostomy area larger. In the other patients the closure procedure was completed easily with the mini elliptic incision around the ostomy only. The duration of the surgical closure was 40 (25-65) minutes. In the post-operative follow-ups 9 patients showed complications requiring no surgical intervention (Table 2). The most frequent complication was wound site infection.

Discussion

Colostomy is preferred for many reasons. It is performed either as permanent or temporary depending on the condition of the

patient. Ostomy is temporarily needed especially in such cases as pelvic sepsis, sphincter repair, and perineal injuries. The goal is to prevent intestinal content from leaking into the site to be protected. To this end, the ostomy used is required to be as divertive as possible. Loop ostomies are not completely divertive and allow the passage of intestinal content into the distal [7,8]. End ostomies are preferred to prevent this undesired situation. We define a new end ostomy which has many advantages with the new technique we used. One of the most important advantages is its being fully divertive.

One of the methods that can be preferred as end ostomy is Hartmann's Colostomy. When the rectal stump happens to be rather short in patients selected for Hartmann's colostomy, coloanal anastomosis to be performed turns out to be difficult and risky. It becomes permanent especially in elderly and feeble patients. Even if the rectal stump is left long, a more risky and longer operation such as laparotomy or laparoscopy is needed [9]. In the technique we use the colon is prepared in the shape of a loop without damaging the intestinal integrity and fully divertive ostomy is formed. Since no large defect in the mesocolon is formed, no damage is inflicted on the marginal artery and mesenteric neural structures.

Closure of end colostomy is a risky procedure. The complication rate in a study conducted by Garber A et al. [10] was reported to be 29%. Hospital mortality rate, on the other hand, was revealed to be 2%. The duration of operation was reported to be longer than 7 hours. In the series by Zarnescu Vasiliu et al. [11] the major morbidity rate was indicated to be 16.1%. 3.6% of these complications was designated to be anastomotic leakage. It is possible to see in literature that studies have demonstrated that the complication of ostomy closure was 41%. Kxairaluoma et al. reported in their study that they did not close one third of the opened ostomies. In the technique we use, the rate of complication was 18.8%, all of which were minor ones. No mortalities were seen. The most frequent complication we came across was surgical site infection. The surgical duration was 40 minutes on average. No case of failure to close the ostomy was seen. No wide dissection and bridectomy was required.

Conclusion

Colon integrity is preserved with this technique. A complete diversion is achieved. Closure of uncut end colostomy is managed by means of a simple surgical procedure. If we want to close colostomy without having to perform laparotomy, uncut diverting end colostomy is a good choice.

References

1. Cataldo PA. Technical tips for stoma creation in the challenging patient. *Clin Colon Rectal Surg.* 2008; 21: 17-22.
2. ZarnescuVasiliu EC, Zarnescu NO, Costea R, Rahau L, Neagu S. Morbidity after reversal of Hartmann operation: retrospective analysis of 56 patients. *J Med Life.* 2015; 8: 488-491.
3. Garber A, Hyman N, Osler T. Complications of Hartmann takedown in a decade of preferred primary anastomosis. *Am J Surg.* 2014; 207: 60-64.
4. Haughn C, Ju B, Uchal M, Arnaud JP, Reed JF, Bergamaschi R. Complication rates after Hartmann's reversal: open vs. laparoscopic approach. *Dis Colon Rectum.* 2008; 51: 1232-1236.
5. Akcan A, Sözüer E, Akyıldız H, Yılmaz N, Küçük C, Ok E. Necessity of preventive colostomy for Fournier's gangrene of the anorectal region. *Ulus Travma Acil Cerrahi Derg.* 2009; 15: 342-346.
6. Bedirli A, Şakrak Ö, Sözüer EM, İnce Ö, Kerek M, Yılmaz K. Surgical management of acute-bowel obstructions caused by left colon tumor. *Turk J Surg.* 2002; 18: 174-180.
7. Kehlet H, Wilmore DW. Fast-track surgery. *Br J Surg.* 2005; 92: 3-4.
8. Harald R. Stomas and Stomatherapy. Rosen Herold A, Leher PA, Matzel KE, O'Connell PR. *Coloproctology: Edition 2.* Springer-Verlag Berlin Heidelberg. 2017; 334-340.
9. Martin ST, Vogel JD. Intestinal stomas: indications, management, and complications. *Adv Surg.* 2012; 46: 19-49.
10. Banerjee S, Leather AJ, Rennie JA, Samano N, Gonzalez JG, Papagrigoriadis S. Feasibility and morbidity of reversal of Hartmann's. *Colorectal Dis.* 2005; 7: 454-459.
11. Kairaluoma M, Rissanen H, Kultti V, Mecklin JP, Kellokumpu I. Outcome of temporary stomas. A prospective study of temporary intestinal stomas constructed between 1989 and 1996. *Dig Surg.* 2002; 19: 45-51.