

## Case Report

# Congenital Junctional Ectopic Tachycardia: A Case Report of Two Siblings

Sekhar JC<sup>1\*</sup>, Relan J<sup>2</sup> and Meena P<sup>1</sup>

<sup>1</sup>Senior Resident, Department of Pediatrics, Maulana Azad Medical College and associated Lok Nayak Hospital, New Delhi, India

<sup>2</sup>Senior Resident, Department of Cardiology, All India Institute of Medical Sciences, New Delhi, India

\*Corresponding author: Dr. Jerin C Sekhar, Senior Resident, Department of Pediatrics, Maulana Azad Medical College and associated Lok Nayak Hospital, New Delhi, India

Received: April 18, 2019; Accepted: May 07, 2019;

Published: May 14, 2019

## Abstract

Congenital junctional ectopic tachycardia is a unique supraventricular tachyarrhythmia that is frequently intractable to medical therapy. Most cases described have been sporadic with a few studies reporting familial cases. We report two siblings with congenital JET, born of consanguineous marriage, who required multiple anti-arrhythmics for control. The inheritance of congenital JET may be autosomal recessive and an extensive whole genome approach of the involved family is likely to be helpful in the candidate gene search. Early clinical and electrophysiological identification is imperative to reduce mortality.

**Keywords:** Junctional Ectopic Tachycardia; Congenital; Inheritance; Familial

## Introduction

Congenital junctional ectopic tachycardia (JET) is a unique supraventricular tachyarrhythmia presenting in the first six months of life, associated in upto 60% cases with cardiomegaly and/or heart failure [1]. Unlike the postoperative variety that is usually self-limiting, the congenital variety persists in 90% cases. It is frequently intractable to medical therapy and associated with significant mortality. However, with the introduction of amiodarone, it has become amenable to treatment [2]. Most cases described have been sporadic with a very few studies in literature reporting familial cases [1,3]. In one study, TNNI3K gene mutation was identified as the likely cause [4]. We report two siblings with congenital JET who were born out of a consanguineous marriage and required multiple antiarrhythmic drugs for control.

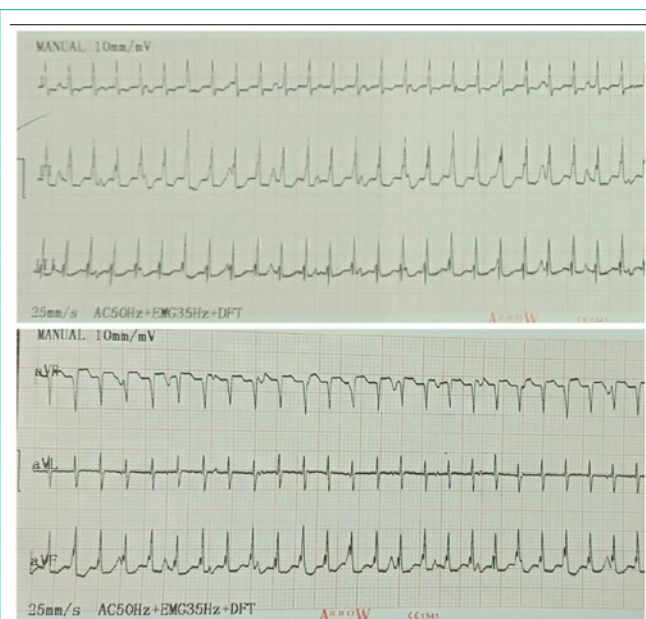## Case Presentation

A 27-day-old female child born of a consanguineous marriage presented to the emergency with lethargy, poor feeding and fast breathing for one day. She was in cardiogenic shock with tachycardia (190/min), hepatomegaly and S3 gallop. She improved over the initial 12 hours with dobutamine infusion, oxygen and restricted intravenous fluids. At 18 hours of admission, she had a heart rate exceeding 250/min. An electrocardiogram revealed a narrow QRS tachycardia with Atrio-Ventricular (AV) dissociation with an atrial rate of 150/min and a ventricular rate of 250/min, suggestive of congenital junctional ectopic tachycardia (Figure 1). Amiodarone, with a loading dose of 5mg/kg followed by an infusion at 10µg/kg/min, suppressed the heart rate to around 210/min. Digoxin given 12 hours after the amiodarone loading induced ventricular ectopics and hence further doses were withheld. Propranolol at 2mg/kg/day was added 24 hours after the start of amiodarone. The heart rate reduced to 110/min after 48 hours of anti-arrhythmics. Echocardiography revealed severe left ventricular dysfunction (ejection fraction: 20–25%) without any evidence of a structural heart disease, suggestive of tachycardiomyopathy and hence enalapril was started. She had a satisfactory ventricular rate control on amiodarone and propranolol and was discharged.

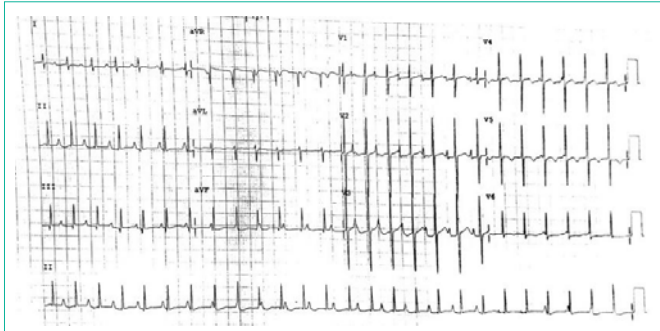
The elder male sibling of this child currently aged three years was also diagnosed as a case of congenital JET at 40 days of life (Figure 2). He had another life-threatening episode of arrhythmias at two years of age and is presently stable on amiodarone, flecainide, metoprolol and enalapril. His recent echocardiography revealed moderate left ventricular systolic dysfunction with an ejection fraction of 45%. The mother of the siblings tested negative for anti-SSA and SSB autoantibodies.

## Discussion

Congenital JET is a rare tachyarrhythmia first reported by Coumel, et al in 1976 [5]. Neonates present with congestive heart failure and echocardiographic evidence of left ventricular dysfunction



**Figure 1:** Electrocardiogram of the index case showing a narrow complex tachycardia with atrioventricular dissociation suggestive of congenital junctional ectopic tachycardia.



**Figure 2:** Electrocardiogram of the elder sibling showing narrow QRS complexes with atrioventricular dissociation.

and the clinical status is related to the ventricular rate at presentation [3]. Its association with congenital heart disease has been reported to be sporadic. The diagnosis is based on electrocardiographic evidence of a narrow complex tachycardia and AV dissociation [6].

The electrophysiological mechanism is thought to be abnormal automaticity within the AV node or the proximal bundle of His. Cardioversion and overdrive pacing are generally ineffective and the tachycardia can evolve into other unstable rhythms [7]. When there is retrograde conduction, adenosine infusion can rule out AV reciprocating tachycardia, because of tachycardia cycle lengthening without termination of the arrhythmia [8].

Treatment is indicated in infants with symptoms, ventricular dysfunction or rapid rates to control the arrhythmia and suppress the rate to tolerable levels to prevent heart failure [9]. A review of the pharmacotherapy has revealed a high failure rate, with amiodarone having the highest response rates [1,3]. Sporadic reports of efficacy also exist about propafenone, flecainide/encainide, sotalol and ivabradine. Digoxin does not affect the ventricular rate and has been demonstrated to be not completely safe [1]. Catheter ablation can be a definitive option in critically ill patients, when drugs fail or when tachycardia becomes chronic [6]. Surgical His bundle ablation has yielded contrasting results.

More interest is attributed to this arrhythmia, as it is familial. Villain et al reported a familial history of JET positive in 50% children [1]. In yet another study by Sarubbi et al, up to three members of the same family were affected, with a family history recognised in up to 55.6% patients [3]. These suggest a possible Mendelian inheritance. A Canadian study using whole exome sequencing identified a

heterozygous p.Thr539Ala mutation in *TNNI3K*, a cardiac-specific kinase, as the likely cause for a novel familial cardiac conduction disease including congenital JET [4]. An extensive whole genome approach of the family is likely to be helpful in the candidate gene search.

Congenital JET is associated with a high mortality; up to 34% [1] sporadic cases of sudden death have been attributed to a dramatic evolution to paroxysmal complete AV block. Hence, clinical and electrophysiological identification and early treatment of the arrhythmia is imperative in such children to reduce mortality due to a treatable cause.

## Contributors

JCS and PM collected the clinical details, managed the patient, reviewed the literature and drafted the manuscript; JR supervised the management, reviewed and edited the manuscript.

## References

- Villain E, Vetter VL, Garcia JM, Herre J, Cifarelli A, Garson A Jr. Evolving concepts in the management of congenital junctional ectopic tachycardia. A multicenter study. *Circulation* 1990; 81: 1544–1549.
- Collins KK, Van Hare GF, Kertesz NJ, Law IH, Bar-Cohen Y, Dubin AM, et al. Pediatric non-postoperative junctional ectopic tachycardia medical management and interventional therapies. *J Am Coll Cardiol*. 2009; 53: 690-697.
- Sarubbi B, Musto B, Ducceschi V, D'Onofrio A, Cavallaro C, Vecchione F, et al. Congenital junctional ectopic tachycardia in children and adolescents: a 20 year experience based study. *Heart*. 2002; 88: 188-190.
- Xi Y, Honeywell C, Zhang D, Schwartzentruber J, Beaulieu CL, Tetreault M, et al. Whole exome sequencing identifies the *TNNI3K* gene as a cause of familial conduction system disease and congenital junctional ectopic tachycardia. *Int J Cardiol*. 2015; 185: 114-116.
- Coumel P, Fidelle JE, Attuel P, Brechenmacher C, Batisse A, Bretagne J, et al. [Congenital bundle-of-his focal tachycardias. Cooperative study of 7 cases]. *Arch Mal Coeur Vaiss*. 1976; 69: 899-909.
- Sarubbi B, Vergara P, D'Alto M, Calabro R. Congenital junctional ectopic tachycardia: presentation and outcome. *Indian Pacing Electrophysiol J*. 2003; 3: 143-147.
- Henneveld H, Hutter P, Bink-Boelkens M, Sreeram N. Junctional ectopic tachycardia evolving into complete heart block. *Heart*. 1998; 80: 627–628.
- Rossi AF, Kipel G, Golinko RJ, Griep RB. Use of adenosine in postoperative junctional ectopic tachycardia with 1:1 retrograde atrial conduction. *Am Heart J*. 1991; 121: 1237-1239.
- Wren C. Incessant tachycardias. *Eur Heart J*. 1998; 19: E54-59.