

## Case Report

# Treating a Simultaneous Presentation of Multiple Myeloma and Hodgkin's Lymphoma

Shervani S<sup>1\*</sup>, Durham C<sup>1</sup>, Williams C<sup>2</sup>, Surapaneni R<sup>2</sup> and Mirkes C<sup>1</sup>

<sup>1</sup>Department of Internal Medicine, Texas A&M Health Science Center College of Medicine and Baylor Scott and White Memorial Hospital

<sup>2</sup>Division of Hematology and Oncology, Texas A&M Health Science Center College of Medicine and Baylor Scott and White Memorial Hospital

\*Corresponding author: Shervani S, Department of Internal Medicine, Texas A&M Health Science Center College of Medicine and Baylor Scott and White Memorial Hospital, 2401 S. 31st Street, Temple, TX 76508, USA

Received: April 16, 2018; Accepted: May 07, 2018;

Published: May 21, 2018

## Abstract

There are few published case reports of the simultaneous presentation of Multiple Myeloma and Hodgkin's Lymphoma (HL). Several case reports document sequential diagnosis of HL after MM, especially after therapy including autologous stem cell transplant (ASCT) for MM. However our case is rare as it describes the symptomatic presentation of MM and HL diagnosed concurrently – before any therapies were initiated. We present a case of a 66-year-old woman who presented to the emergency department for hip pain and was found to have multiple lytic lesions and periaortic lymphadenopathy, leading to a diagnosis of both MM and HL. Accurately diagnosing both malignancies had significant impact on the selection of initial therapy, though choosing an effective treatment regimen for both malignancies is a challenge as there are no clear guidelines to follow in this rare situation. This case highlights the importance of investigating the etiology of pathologic lymphadenopathy in a patient with MM, and also proposes a successful treatment regimen for a patient diagnosed with simultaneous MM and HL.

**Keywords:** Multiple myeloma; Hodgkin's lymphoma; Lymphadenopathy; Treatment

## Introduction

Hodgkin's Lymphoma (HL) is a B cell neoplasm arising from germinal center or post germinal center B cells. Multiple Myeloma is a neoplastic proliferation of plasma cells (derived from B cells) that produce a monoclonal immunoglobulin. Several case reports describe sequential diagnosis of HL after MM especially after autologous stem cell transplant for MM. However, the presentation of HL and MM diagnosed concurrently, prior to initiating any therapy, is far more rare and presents a unique diagnostic and treatment challenge, as illustrated by this case. MM does not present with lymphadenopathy, which led to further workup and diagnosis of a second malignancy in this patient. Treatment included ABVD therapy, dexamethasone, and zoledronic acid injections concurrently, which were then followed by bortezomib and dexamethasone.

## Case Presentation

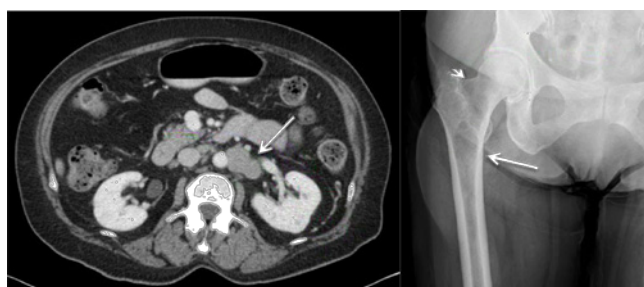A 66-year-old woman with a history of diabetes mellitus type II and hypertension presented to the emergency department for right hip pain and 20 pound weight loss. The patient had tenderness to palpation over the right hip and back. There was no palpable lymphadenopathy. She was found to have multiple lytic osseous lesions involving the proximal right femur (Figure 1), L4 vertebral body, and left seventh rib on computerized tomography. Periaortic (Figure 1), porta hepatic, and aortocaval lymphadenopathy was also noted. She underwent cephalomedullary nailing of the right femur for a pathologic fracture.

Pathology from right hip surgical biopsy demonstrated plasmacytoma, with sheets of plasma cells staining positive for CD138 (Figure 2). The plasma cell population was monoclonal for kappa and IgG and minimal staining was identified with IgA, IgD,

IgM, and lambda. No significant staining was appreciated with CD10 and cyclin D1. Normocytic anemia was present, but the patient had normal kidney function. Serum and urine electrophoresis immunofixation showed a monoclonal protein spike in the gamma region of 0.5 mg/dL. Immunoglobulin free light chains of the serum were significant for an IgG free kappa light chain level of 64.50 mg/dL and elevated kappa/lambda free light chain ratio of 26. Bone marrow biopsy showed variable cellularity (30-50%) with active trilineage hematopoiesis and 10% polyclonal plasmacytosis, not consistent with bone marrow involvement. The patient was diagnosed with stage II MM based on the Durie Salmon staging system. Eight fractions of radiation therapy were provided to the right hip, pelvis, and L4.

Positron emission tomography-computed tomography (PET-CT) demonstrated, in addition to lytic lesions, hypermetabolic adenopathy in the abdomen and mediastinum. Two right inguinal lymph node biopsies were performed with pathology showing benign fat infiltration. With a high suspicion for pathologic lymphadenopathy, a repeat biopsy of a retroperitoneal lymph node was performed and demonstrated classical nodular sclerosing HL. Immunohistochemistry stains showed neoplastic cells that were CD30, CD15, and PAX5 positive (Figure 2). They were CD45, CD3, and CD20 negative. Epstein-Barr virus latent membrane protein was also negative. Staging of HL was difficult considering an overlapping diagnosis of symptomatic MM but was considered stage III with lymphatic involvement above and below the diaphragm by the Ann Arbor staging system.

Initial treatment was determined at a multidisciplinary tumor board. For treatment of HL, the patient was started on doxorubicin, bleomycin, vinblastine, and dacarbazine (ABVD) therapy and underwent six cycles. Bleomycin was not given in cycle number



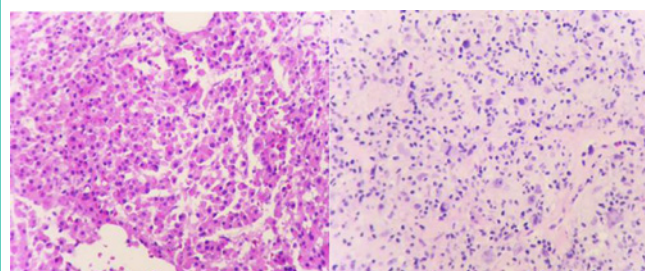
**Figure 1:** (Left) Computed tomography with contrast of the abdomen demonstrated periaortic adenopathy measuring up to 4.9 cm (arrow). (Right) Two lytic lesions (arrows) identified on magnetic resonance imaging in the right proximal femur.

six due to lung toxicity. Treatment for consisted of 20 mg of dexamethasone weekly and 4 mg zoledronic acid injections every 4 weeks while she received ABVD chemotherapy. She subsequently demonstrated regression of her lymphadenopathy with a Deauville criteria of one on the final PET-CT, but the bone lesions remained hypermetabolic. Biopsy of the sacral bone lesion confirmed active MM. Electrophoresis showed reduction in the IgG Kappa M protein spike (from 0.5 to 0.1 mg/dL) and reduction of the kappa/lambda free light chain ratio after treatment of HL with ABVD and weekly dexamethasone. Treatment for MM was initiated after completion of ABVD, with weekly bortezomib subcutaneous injections and oral dexamethasone for a total of 16 cycles. She was evaluated for autologous bone marrow transplant but deemed not to be a suitable candidate due to her comorbidities. The patient has been followed without progression of disease for over two years.

## Discussion

MM does not present with lymphadenopathy, which prompted further investigation in our patient. In this case, the patient was found to have a second malignancy. If the diagnosis of HL was not made it may have resulted in significant morbidity and mortality for the patient from an otherwise curable disease. Therapeutic management was complicated by two different malignancies with different treatment regimens. Based on previous case reports and interdisciplinary meetings, it was decided to first focus treatment on the curable disease, HL, and concurrently provides partial treatment for MM. After radiation therapy for the MM bone lesions, treatment with ABVD was initiated for HL and well as oral dexamethasone and zoledronic acid injections for MM. The diagnosis of HL prior to initiating therapy for MM was significant in that different regimens reserved for more aggressive treatment of MM would have been used had the second diagnosis not been made, such as bortezomib, lenalidomide, and dexamethasone.

There are a handful of published case reports of concurrent presentations of MM and HL prior to initiating treatment [1-6]. Some of these cases describe similar treatment regimens involving initial use of ABVD therapy. One case describes the diagnosis of HL after bortezomib and dexamethasone were initiated for the treatment of MM [7]. Bortezomib and dexamethasone were stopped with the diagnosis of HL, and ABVD therapy initiated. Another case describes delayed diagnosis of HL after MM was diagnosed and treatment had to be altered [8]. An international study used the addition of



**Figure 2:** Right femur bone biopsy (left) was almost entirely occupied by sheets of plasma cells, supported with CD138. Staining notable for monoclonal populations of kappa and IgG. Immunohistochemistry stains from the retroperitoneal lymph node biopsy (right) were CD30, CD15, and PAX5 positive.

thalidomide to the standard AVBD regimen [3]. In this study, the patient declined transplantation and was given continued cycles of dexamethasone and thalidomide to avoid disease progression. All studies treated with chemotherapy until complete remission of HL was achieved and then preceded to ASCT if possible. We present a regimen in which AVBD therapy, dexamethasone, and zoledronic acid injections are provided concurrently followed by bortezomib and dexamethasone.

Considering that MM is derived from B cells that mature into plasma cells and that HL is derived from germinal B cells, it is rational to theorize that similar risk factors causing one malignancy may then trigger evolution of the other malignancy [9-12]. In fact, one recent study describes the identification of genetic risk factors related to the development of B cell malignancies [13]. These risk factors involved specific loci that were found to cause pleiotropic effects on the regulation of the B cell pathway, resulting in either increased or decreased risk of developing MM, HL, and chronic lymphocytic leukemia. This pathway not only describes how multiple B cell pathway related malignancies may occur subsequently or concurrently but also suggests possible therapeutic targets for these malignancies in the future.

Our case illustrates two main concepts: the importance of investigating the etiology of pathologic lymphadenopathy despite an initial negative biopsy, and a successful treatment regimen used in a patient diagnosed with simultaneous HL and MM.

## References

1. Ibarrola de Andrés C, Toscano R, Lahuerta JJ, Martínez-González MA. Simultaneous occurrence of Hodgkin's disease, nodal Langerhans' cell histiocytosis and multiple myeloma IgA(kappa). *Virchows Arch.* 1999; 434: 259-262.
2. Ibbotson RM, Revell PA, Molland EA, Minton MJ. The simultaneous presentation of Hodgkin's disease of myeloma. *Postgrad Med J.* 1977; 53: 52-53.
3. Huang C, Zhao G, Wang L, Zhang H, Wu X, Zhang M, et al. Simultaneous occurrence of Hodgkin's lymphoma and multiple myeloma: A case report and review of the literature. *Oncol Lett.* 2016; 11: 4139-4143.
4. Huppmann AR, Liu ML, Nava VE. Concurrent diagnoses of Hodgkin lymphoma and biclonal myeloma in the bone marrow. *Ann Diagn Pathol.* 2010; 14: 268-272.
5. Bichel J. Coincidence of Hodgkin's disease and myelomatosis. *Acta Med Scand.* 1957; 157: 399-400.
6. Sacks PV, Tavassoli M, Eastlund DT. Simultaneous occurrence of myeloma

- and Hodgkin's disease. *Acta Haematol.* 1976; 55: 118-122.
7. Chandran R, Simon M, Spurgeon SE. Concurrent presentation of hodgkin lymphoma and multiple myeloma. *Case Rep Hematol.* 2013; 2013: 398769.
  8. Lalayanni C, Theodoridou S, Athanasiadou A, Saloum R, Tsatalas C. Simultaneous occurrence of multiple myeloma and Hodgkin's disease. A case report. *Haematologica.* 200; 85: 772-773.
  9. Schinasi LH, Brown EE, Camp NJ, Wang SS, Hofmann JN, et al. Multiple myeloma and family history of lymphohaematopoietic cancers: Results from the International Multiple Myeloma Consortium. *Br J Haematol.* 2016; 175: 87-101.
  10. Weisenberg E, Anastasi J, Adeyanju M, Variakojis D, Vardiman JW. Hodgkin's disease associated with chronic lymphocytic leukemia. Eight additional cases, including two of the nodular lymphocyte predominant type. *Am J Clin Pathol.* 1995; 103: 479-484.
  11. Hasskarl J, Ihorst G, De Pasquale D, Schröttner P, Zerweck A, et al. Association of multiple myeloma with different neoplasms: systematic analysis in consecutive patients with myeloma. *Leuk Lymphoma.* 2011; 52: 247-259.
  12. Gelmann EP, Dennis LH. Plasma-cell dyscrasia after alkylating-agent therapy for Hodgkin's disease. *N Engl J Med.* 1981; 305: 1350.
  13. Law PJ, Sud A, Mitchell JS, Henrion M, Orlando G, Lenive O, et al. Genome-wide association analysis of chronic lymphocytic leukaemia, Hodgkin lymphoma and multiple myeloma identifies pleiotropic risk loci. *Sci Rep.* 2017; 7: 41071.