

## Case Report

# Central Pontine Myelinolysis Complicating Hodgkin Lymphoma: A Case Report & Review of Literature

Akansha Garg\*

Departments of Hematology and Pathology, Sanjay Gandhi Postgraduate Institute of Medical Sciences, Lucknow, Uttar Pradesh, India

\*Corresponding author: Akansha Garg, Departments of Hematology and Pathology, Sanjay Gandhi Postgraduate Institute of Medical Sciences, Lucknow, Uttar Pradesh, India

Received: May 23, 2022; Accepted: June 21, 2022;

Published: June 28, 2022

## Abstract

Central Pontine myelinolysis is a demyelinating disorder generally caused by rapid correction of hyponatremia and is a debilitating condition. Here we describe an interesting case of a 38 year old man diagnosed with Hodgkin lymphoma who developed CPM prior to start of the first cycle of chemotherapy with no antecedent hyponatremia and had complete neurological recovery.

## Introduction

Central pontine myelinolysis (CPM) is a neurological disorder characterized by non-inflammatory demyelination affecting the central part of the basis pontis (pons) [1]. Rapid osmotic shifts between the neurons & interstitium is suggested to be the putative explanation for its occurrence. Rapid correction of the hyponatremia, malnutrition, chronic alcoholism and liver disorders are among the most frequent causes of CPM in clinical practice [1]. CPM is one of the rare complications of the advanced Hodgkin disease [2]. Here we describe an interesting case of a 38 year old man diagnosed with Hodgkin lymphoma who developed CPM prior to start of the first cycle of chemotherapy with no antecedent hyponatremia and had complete neurological recovery.

## Case Report

A 38 year old male presented in September 2020 with complaints of fever, generalized weakness and lethargy for 3 months. There was history of night sweats & significant weight loss (9 kg in last 2 months). On examination he had pallor, generalized lymphadenopathy (largest cervical node 2.5cmx2.0cm) and palpable spleen 5 cm below the costal margin. Laboratory examination revealed Hemoglobin of 7.2 gm/dL, white blood cell count  $7.3 \times 10^3/\mu\text{L}$  with a normal differential and platelet count of  $293 \times 10^3/\mu\text{L}$ . Serum electrolytes were normal with serum Sodium 132 mEq/L. Other laboratory data included total bilirubin 0.7 mg/dL, albumin 3.5 g/dL, Aspartate Aminotransferase (AST) 65 IU/L, Alanine Aminotransferase (ALT) 22 IU/L, Lactate dehydrogenase (LDH) 956 U/L,  $\beta_2$  microglobulin 4.6 mg/L, Erythrocyte sedimentation rate (ESR) 57 mm/hr. Serology for HIV, Hepatitis B & hepatitis C was negative. An excisional cervical lymph node biopsy revealed large atypical lymphoma cells located within sub-capsular and para-cortical regions. Immunohistochemistry indicated positive staining for CD20, Bcl-2 and Bcl-6. CD3, CD30, S-100, CD31, CD34 were negative. The diagnosis of mixed cellularity Hodgkin lymphoma was established. Bone marrow aspiration & biopsy showed presence of lymphomatous infiltration. The patient was planned for ABVD (Adriamycin, Bleomycin, Vinblastine, Dacarbazine) chemotherapy.

On Day 2 of admission prior to the start of chemotherapy he developed a sudden onset generalized tonic clonic seizures along

with loss of consciousness. The seizures were controlled with anticonvulsants and MRI brain (contrast) was done with FLAIR images showing hyperintensity involving central pons with sparing of the periphery, suggestive of osmotic central pontine myelinolysis (Figure 1A and 1B). Rest of the brain areas were normal. Laboratory investigations revealed serum sodium 134 meq/l, serum potassium 3.8 meq/l, serum ionized calcium 0.89 meq/l, and serum phosphate 4.2 meq/l. Lumbar puncture was done to rule out any infective etiology which showed protein 43 mg/dl, sugar 63 mg/dl, along with cultures (bacterial & fungal) which were sterile. The patient was continued on supportive care on which he improved with no apparent focal neurological deficit. He was administered ABVD chemotherapy after neurological recovery which he tolerated well. He completed 6 cycles of ABVD chemotherapy in March 2021 after which repeat MRI brain was done that showed resolution of lesions.

Whole body PET CT done for the evaluation of the disease after completion of the therapy was suggestive of complete remission. Presently the patient is doing well and is under our regular follow up and does not have any neurological issues.

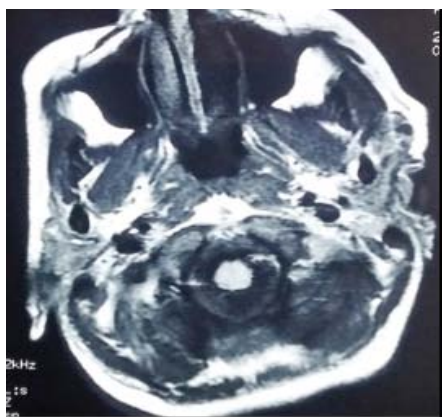
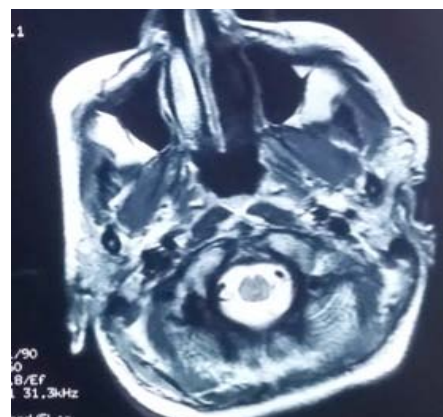
## Discussion

Since the original description of CPM by Adams & colleagues in 1959, several case series have been published associating it to the rapid sodium correction as its most important cause [1]. Rapid correction of the hyponatremia causes sudden rise in the tonicity in the interstitium surrounding the neuron which cannot be compensated at a rate commensurate with the production or regeneration of intracellular organic osmoles (such as myoinositol, taurine, and glutamate); thereby leading to cell shrinkage and loss of oligodendrocytes & myelinolysis [3]. Chronic alcoholism, malnutrition, liver disorders, rapid correction of the hyponatremia & use of chemotherapeutic agents known to cause hyponatremia are important risk factors for the development of CPM [4]. Chronic alcoholism, malnutrition, liver disorders predispose to the reduced synthesis and/or regeneration of these intracellular organic osmoles [4].

The clinical features of CPM are quite variable ranging from completely asymptomatic cases to patients presenting with neuropsychiatric symptoms (such as disinhibition, emotional

**Table 1:** Clinical profile of reported CPM cases in Hodgkin's Lymphoma in relation to putative risk factors.

S. No	Age /Sex	Disease Stage	Duration of illness	Liver Involvement	Electrolytes Imbalance	Nutritional status	Prior Chemotherapeutic drugs usage	Outcome	Ref
1.	7yr/M (1971)	IVB	-	Present	None	Poor (S.albumin 1.4gm%, Total Serum Proteins 4.2gm%)	Received Chemotherapy (Vincristine, Chlorambucil & prednisone)	Died	2'
2.	9yr/M (1979)	IV	-	Present	Present (S.sodium 112meq/L)	Poor	Prior to receiving chemotherapy	Died	6'
3.	28yr/M (1981)	IV	3 months	Present	Present (S. sodium 129 mmol/L)	Normal	Received Chemotherapy (Procarbazine, Dexamethasone, Vinblastine)	Died	7'
4.	12yr/M (1993)	IVB	3 months	none	None	Poor (S. albumin 1.7gm%, Total Serum Proteins 5.5gm%)	Prior to receiving Chemotherapy	Alive	8'
5.	63yr/F (2015)	IVB	-	none	Present (S. Sodium 98meq/l)	-	Received Chemotherapy (ABVD cycle IA)	Alive	9'
6.	38 yr/M (2021) (present case)	IVB	2 months	Not Present	Not Present	Normal	Prior to start of chemotherapy	Alive	

**Figure 1A:** MRI Brain: FLAIR image showing hyper intensity in the central Pons with sparing of the periphery.**Figure 1B:** T1W hypo intense image with diffuse restriction of the central Pons.

lability, bizarre behavior) and/or neurologic symptoms (such as confusion, seizures, impaired cognition, dysarthria, dysphasia, gait instability, weakness/paralysis). Neuroimaging plays an important role in establishing the diagnosis as it is associated with characteristic radiological findings. MRI (contrast) is better than CT scan in delineating the lesion. MRI shows hyperintense lesions in the central pons on T2 weighted and FLAIR images (Figure 1.A) and hypointense lesion on T1W images (Figure 1.B) with diffusion restriction as was present in the present case [5].

Central pontine myelinolysis has been reported to be associated with haematological malignancies like Acute lymphoblastic Leukemia, Acute Myeloid Leukemia, Non- Hodgkin Lymphoma (Diffuse Large B cell Lymphoma). However there are only five patients of hodgkin lymphoma reported in the literature till date to have developed this condition. All the patients who developed CPM had advanced disease (stage IV) at presentation (as shown in Table 1). However three patients had extensive hepatic involvement with the disease, three

had concomitant hyponatremia at presentation & two patients had very low total serum proteins with hypoalbuminemia; all of which are important risk factors for the occurrence of CPM.

Our case is unique as it had none of the above mentioned risk factors. In the absence of histopathological diagnosis of the pontine lesions, other diagnostic possibilities should be considered. A possibility of intracranial involvement with hodgkin lymphoma or 2nd malignancy should be entertained. However the typical location of the lesion, the absence of enhancement of lesion on MRI and presence of lesion prior to the start of therapy argues against these possibilities. Another diagnostic possibility could be the occurrence of paraneoplastic neurological syndrome well documented with Hodgkin lymphoma. The paraneoplastic cerebellar degeneration & limbic encephalitis (Ophelia Syndrome) can also present with motor dysfunction, marked ataxia & neuropsychiatric symptoms. However, MRI imaging findings in the present case refute the diagnosis as the former is usually associated with normal MRI brain findings & latter

is associated with hyperintensities in the left hippocampus and medial temporal lobe on T2-weighted images.

## Conclusion

Though rare, the possibility of CPM should be entertained in cases of advanced Hodgkin lymphoma presenting with neurological symptoms especially in presence of risk factors like alcoholism, malnutrition, hepatic involvement & rapid correction of hyponatremia. To the best of our knowledge, our case is unique as it had none of the risk factors frequently associated with CPM with complete neurological recovery and successful treatment outcome with chemotherapy.

## References

1. ADAMS RD, VICTOR M, MANCALL EL. Central pontine myelinolysis: a hitherto undescribed disease occurring in alcoholic and malnourished patients. *A.M.A. archives of neurology and psychiatry*. 1959; 81(2): 154. doi:10.1001/ARCHNEURPSYC.1959.02340140020004.
2. Valsamis MP, Peress NS, Wright LD. Central pontine myelinolysis in childhood. *Archives of neurology*. 1971; 25(4): 307-312. doi:10.1001/ARCHNEUR.1971.00490040033004.
3. Kleinschmidt-DeMasters BK, Norenberg MD. Rapid correction of hyponatremia causes demyelination: relation to central pontine myelinolysis. *Science*. 1981; 211(4486): 1068-1070. doi:10.1126/SCIENCE.7466381.
4. Bhat S, Koulaouzidis A, Haris M, Tan C. Central pontine myelinolysis. *Annals of hepatology*. 2006; 5(4): 291-292. doi:10.1016/S1665-2681(19)31991-X.
5. Miller GM, Baker HL, Okazaki H, Whisnant JP. Central pontine myelinolysis and its imitators: MR findings. *Radiology*. 1988; 168(3): 795-802. doi:10.1148/RADIOLOGY.168.3.3406409.
6. Wright DG, Lauren R, Victor M. Pontine and extrapontine myelinolysis. *Brain : a journal of neurology*. 1979; 102(2): 361-385. doi:10.1093/BRAIN/102.2.361.
7. Lai C, Tan C, Lin S, Chen H. Central pontine myelinolysis. *Canadian Medical Association Journal*. 2011; 183(9): E605-E605. doi:10.1503/cmaj.090186.
8. Chintagumpala MM, Mahoney DH, McClain K, Dreyer ZE, Fishman MA, Carrol CL, et al. Hodgkin's disease associated with central pontine myelinolysis. *Medical and pediatric oncology*. 1993; 21(4): 311-314. doi:10.1002/MPO.2950210416.
9. Babanrao SA, Prahladan A, Kalidos K, Ramachandran K. Osmotic myelinolysis: Does extrapontine myelinolysis precede central pontine myelinolysis? Report of two cases and review of literature. *The Indian Journal of Radiology & Imaging*. 2015; 25(02): 177-183. doi:10.4103/0971-3026.155870.