

## Case Report

# A Rare Case of a Left Ovarian Remnant Syndrome Associated with a Symptomatic Right Ovarian Cyst

Cyrille NC<sup>1,2</sup>, Annick MNJ<sup>1,2</sup>, Antony MJ<sup>1</sup>, Tatsipie WL<sup>1,2\*</sup>, Etienne B<sup>1,2</sup> and Marie TP<sup>1,3</sup>

<sup>1</sup>Faculty of Medicine and Biomedical Sciences of the University of Yaounde, Cameroon

<sup>2</sup>Endoscopy Surgery and Human Reproductive Teaching Hospital, Cameroon

<sup>3</sup>University Teaching Hospital of Yaounde, Cameroon

\*Corresponding author: Wilfried Loic Tatsipie, Faculty of Medicine and Biomedical Sciences of the University of Yaounde, Cameroon

Received: July 18, 2022; Accepted: August 16, 2022;

Published: August 23, 2022

## Introduction

Ovarian Remnant Syndrome is a rare condition occurring in women who have undergone unilateral or bilateral salpingo-oophorectomy with or without hysterectomy, resulting from the persistence of ovarian tissue left unintentionally after easy or difficult ovarian resection and which becomes functional and/or dystrophic [1]. This syndrome was first described in 1970 by Shemwell and Weed [2] and the first case presented in the literature in 1962 by Kaufmann [3]. This residual ovarian tissue may be asymptomatic or cause pelvic pain or a mass. Risk factors associated with incomplete removal of an ovary and the subsequent development of residual ovarian syndrome are: history of endometriosis, pelvic inflammatory disease, multiple previous surgeries and multiple pelvic adhesions. Patients often present with chronic pelvic pain, pelvic pain associated with a pelvic mass or an asymptomatic pelvic mass. The recommended treatment is surgical removal by laparotomy or laparoscopy [1].

## Observation

We report the case of an ovarian Remnant syndrome in a 39-year-old patient with a history of myomectomy by laparotomy, three caesarean sections, a total hysterectomy with left unilateral oophorectomy indicated for placenta accreta incidentally discovered during the last caesarean section and a laparotomy indicated for bowel obstruction. She came complaining of pain in the right iliac fossa with torsion type of progressive onset, intermittent, with no relieving nor aggravating factor, evolving for 7 days before her admission associated with nausea and profuse sweating relieved with intake of analgesics. The physical examination on admission revealed a renitent pelvic mass in the right iliac fossa of approximately 80mm long axis. She performed an abdomino-pelvic CT scan which found supra-bladder fluid formation with a thick wall (5mm), oval in shape measuring 77\*71\*69 mm with intense peripheral enhancement, medium-abundance pelvic fluid effusion and ovarian formation oval left with fine and regular wall measuring 34\*36\*41mm not raised. A laparocystectomy was indicated and the intraoperative findings were a right ovary with a right hemorrhagic cyst. The left ovary was not visualized but we noted the presence of a cyst of the anterior

## Abstract

Ovarian Remnant Syndrome (ORS) results from the presence of residual ovarian tissue after an ovariectomy. We report the case of a 39-year-old woman with a past history of total abdominal hysterectomy and left salpingo-oophorectomy who presented with pelvic pain and was diagnosed as having ORS. She was successfully operated by laparoscopy with the surgical gesture being the removal of the cyst and the surrounding ovarian tissue with the postoperative course being uneventful.

**Keywords:** Pelvic pain; Ovarian remnant syndrome; Laparoscopy

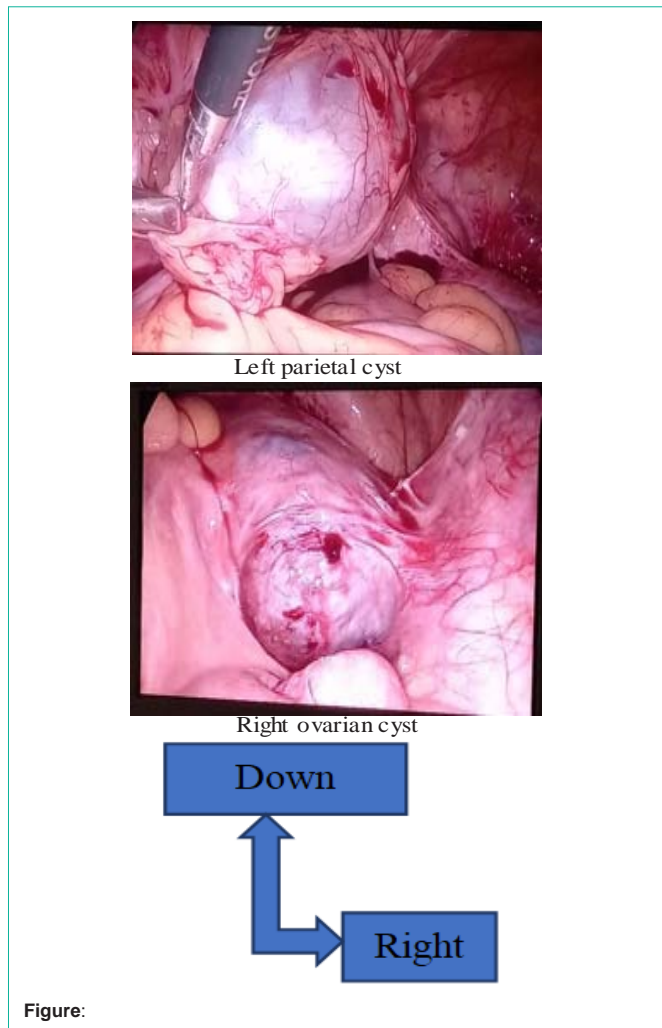
abdominal wall with ovarian tissue measuring 4cm in long axis and looking simple. The management consisted of the complete removal of the cyst and the surgical specimen sent for anatomopathological examination confirming the presence of ovarian tissue on the left specimen. We did a cytectomy on the right side. The post-operative follow-up was unremarkable and the patient was placed under post-operative observation then released 2 days after a favorable evolution.

## Discussion

The diagnosis of residual ovarian syndrome begins with a clinical suspicion obtained through a careful history and knowledge of the syndrome itself. It is supported by a thorough pelvic examination, imaging investigations and laboratory tests [1]. Dense peri-ovarian adhesions and ovarian enlargement can make it difficult to identify ovarian tissue, and they are considered predisposing factors for this disease. These two risk factors are present in severe endometriosis, the most typical pre-existing disease [4].

Patients with this syndrome most often present with symptoms within the first 5 years after oophorectomy, although some reports have shown that patients whose first surgeries dated back more than 20 years ago [4]. Patients most often present with pelvic pain and less frequently with asymptomatic pelvic masses [5]. In the largest cohort of patients (183), reported by the Mayo Clinic, patients who were treated surgically for this syndrome, presenting symptoms include chronic pelvic pain (84%), dyspareunia (26%), cyclic pelvic pain (9%), dysuria (7%) and tenesmus (6%) [6]. In pre-menopausal women, pain symptoms may be caused by an increase in the volume of residual ovarian tissue which may lead to compression of adjacent structures. Pain can also be due to hormonal stimulation ectopic endometriotic implants. In premenopausal patients in whom oophorectomy is performed unilaterally, the manifestation of pain alone often triggers suspicion.

Imaging can be used to aid in diagnosis. Modalities include pelvic ultrasound, CT and MRI. In one study, a complex pelvic mass corresponding to the syndrome was identified in 93, 92 and 78% of cases by ultrasound, CT and MRI respectively, [6]. Similarly in the most recent study, 90% of adnexal mass was detected by ultrasound



[7] which alone seems to be sufficient to highlight the pelvic mass.

The therapeutic options are medical treatment, radiotherapy but the main treatment remains surgery. The pharmacological approach is geared toward suppression of ovarian function and includes oral contraceptives, danazol, and GnRH analogs. A recent study used GnRH in a patient without success, which confirms the limited application of the medical approach [8]. Radiation therapy has also been used as a therapeutic approach. The overall results, however, have been inconsistent. In addition, irradiation without tissue diagnosis has been discouraged due to the discovery of malignancy in residual tissues and potential deleterious effects on adjacent tissues [1,4,9]. Surgical removal with histological confirmation of ovarian tissue remains the reference method [2]. Surgical removal is the main treatment and in addition excision of remaining tissue may require retroperitoneal dissection [4], Ovarian fragments can be difficult to locate and reappearance of new fragments is possible. Surgery can be performed by laparotomy, laparoscopy or robotics [5]. The minimally invasive approach has been the most frequently used, as shown by recent studies with the aim of reducing the morbidity

associated with laparotomy [4,7,9-12]. However, all the authors emphasize the difficulties of this, due to the surgical history and the modification of the anatomical relationships, with a significant risk of visceral complications, involving the digestive and urinary systems, and vascular complications. Price et al. [13], in an analysis of the literature, reported a complication rate of around 16 to 30% after a laparotomy. Regarding the approach, laparoscopy can be proposed as first-line treatment, as it reduces the risk of occurrence of postoperative adhesion complications compared to laparotomy [14,15]. It also leads to lower blood loss and a shorter hospital stay. In the first series by Nezhat and Nezhat [15] comprising 13 patients treated by laparoscopic surgery, 9 had a complete improvement of their painful symptoms.

### References

- Magtibay PM, Margina JF. Ovarian remnant syndrome. *Clin Obstet Gynecol.* 2006; 49: 526-34.
- Shemwell RE, Weed JC. Ovarian Remnant Syndrome. *Obstetrics & Gynecology.* 1970; 36: 299-303.
- Kaufmann JJ. Unusual causes of extrinsic ureteral obstruction. Part 1. *J Urol.* 1962; 97: 319-27.
- Kho RM, Magrina JF, Magtibay PM. Pathologic findings and outcomes of a minimally invasive approach to ovarian remnant syndrome. *Fertility and sterility.* 2007; 87: 1005-1009.
- Kho RM, Abrao MS. Ovarian remnant syndrome: etiology, diagnosis, treatment and impact of endometriosis. *Current Opinion in Obstetrics and Gynecology.* 2012; 24: 210-214.
- Magtibay PM, Nyholm JL, Hernandez JL, Podratz KC. Ovarian remnant syndrome. *American journal of obstetrics and gynecology.* 2005; 193: 2062-2066.
- Arden D, Lee T. Laparoscopic excision of ovarian remnants: retrospective cohort study with long-term follow-up. *Journal of minimally invasive gynecology.* 2011; 18: 194-199.
- B Chung Fat, J-J Terzibachian, V Bertrand, F Leung, T de Lapparent, et al. Ovarianremnant syndrome: diagnostic difficulties and management. *Gynecol Obstet Fertil.* 2009; 37: 488-494.
- Donnez O, Squifflet J, Marbaix E, Jadoul P, Donnez J. Primary ovarian adenocarcinoma developing in ovarian remnant tissue ten years after laparoscopic hysterectomy and bilateral salpingo-oophorectomy for endometriosis. *Journal of minimally invasive gynecology.* 2007; 14: 752-757.
- Mahdavi A, Kumtepe Y, Nezhat F. Laparoscopic management of benign serous neoplasia arising from persistent ovarian remnant. *Journal of minimally invasive gynecology.* 2007; 14: 654-656.
- Chao HA. Ovarian remnant syndrome at the port site. *Journal of minimally invasive gynecology.* 2008; 15: 505-507.
- B Chung Fat, J-J Terzibachian, V Bertrand, F Leung, T de Lapparent, et al. Ovarianremnant syndrome: diagnostic difficulties and management. *Gynecol Obstet Fertil.* 2009; 37: 488-494.
- Price FV, Edwards R, Buchsbaum HJ. Ovarian remnant syndrome: difficulties in diagnosis and management. *Obstetrical & gynecological survey.* 1990; 45: 151-156.
- Kamprath S, Possover M, Schneider A. Description of a laparoscopic technique for treating patients with ovarian remnant syndrome. *Fertility and sterility.* 1997; 68: 663-667.
- Nezhat F, Nezhat C. Operative laparoscopy for the treatment of ovarian remnant syndrome. *Fertility and sterility.* 1992; 57: 1003-1007.