

Case Report

Recurrent Hypoglycemia: Endoscopic Ultrasound to the Rescue

Anikhindi SA^{1*}; Anikhindi AA¹; Bakshi P²; Badwal S²; Belho E³; Mehta N⁴; Kumar A¹; Arora A¹

¹Department of Gastroenterology, Sir Ganga Ram hospital, New Delhi, India

²Department of Pathology, Sir Ganga Ram hospital, New Delhi, India

³Department of Nuclear Medicine, Sir Ganga Ram hospital, New Delhi, India

⁴Department of Surgical Gastroenterology, Sir Ganga Ram hospital, New Delhi, India

*Corresponding author: Anikhindi SA

Consultant, Department of Gastroenterology, Sir Ganga Ram hospital

Tel: +91- 8373956846

Email: dr.anikhindi@gmail.com

Received: July 25, 2023

Accepted: September 06, 2023

Published: September 13, 2023

Abstract

Insulinoma is a rare pancreatic neuroendocrine tumor with an incidence of 4 per million. Ectopic insulinomas are even rarer and comprise 1-2% of these cases. In cases which have established endogenous hyperinsulinemic hypoglycemia, a high-index of suspicion must be maintained since conventional tests like Computed Tomography (CT) and Magnetic Resonance Imaging (MRI) may miss these tumors. Endoscopic ultrasound can be utilised in localisation as it is more sensitive and specific compared to CT or MRI with an added applicability in obtaining a biopsy. However, operator skill and experience play a crucial role in identifying extra-pancreatic insulinomas.

Keywords: Insulinoma; Endoscopic ultrasound; Neuroendocrine tumor; Hypoglycemia

Introduction

Pancreatic neuroendocrine neoplasms account for 2-3% of all pancreatic tumors [1]. Insulinoma is the most common pancreatic neuroendocrine tumor [2-3] with an incidence of 4 per million patients per year [4]. Almost 90% cases are benign in nature and 90% are intra-pancreatic in origin [5-8]. Extra-pancreatic insulinomas are very rare and comprises about 1-2% of all insulinomas [9]. Most of these tumors present with Whipple's triad clinically along with Endogenous Hyperinsulinemic Hypoglycemia (EHH) [10-11].

Diagnosing an insulinoma is often challenging and requires a high index of suspicion and careful assessment. In cases where conventional non-invasive imaging like CT and MRI may often fail to localise these tumors, an endoscopic ultrasound plays often comes to the rescue.

There are very few case reports of extra-pancreatic insulinoma which have been published globally. Here, we present a case of an extra-pancreatic insulinoma localised by endoscopic ultrasound to the pancreatico-duodenal groove.

Case Description

A 44-year-old female presented to the out-patient department with recurrent episodes of dizziness, sweating, palpitations and dryness of mouth over the last 4 months. The episodes were triggered by physical activity and relieved with meals. Patient always kept a snack in her bag to prevent such episodes. There was no history of weight gain. Patient had no history of diabetes mellitus; sulfonyleurea screen was negative. On the basis of history and lab investigation (Table 1) which showed low glucose (65 md/dl), Endogenous Hyperinsulinemic Hypoglycemia (EHH) was suspected. Previous multiple abdominal imaging studies including a Contrast Enhanced Magnetic Resonance (CEMR) of abdomen were normal.

In-view of high clinical suspicion, we proceeded with an endoscopic ultrasound using a linear echoendoscope. Pancreatic survey was normal. On careful evaluation, a Space-Occupying Lesion (SOL) measuring 13x14 mm was seen near the pancreatico-duodenal groove. A trans-gastric fine-needle aspiration was taken for cytopathology (Figure 7).

Table 1: Fasting panel.

Test name	Value	Reference interval
Glucose (fasting)	54 mg/dl	70-100 mg/dl
Insulin (fasting)	42 uIU/ml	2.3-26 uIU/ml
C-peptide (fasting)	4.87 ng/ml	1.1-5.0 ng/ml
Cortisol	22.5 ug/dl	4.46-22.7 ug/dl
Thyroid stimulating hormone	3.81 uIU/ml	0.4 – 4.0 uIU/ml
T3	82 ng/dl	60 – 180 ng/dl
T4	6.4	5 – 12 ug/dl

It revealed showed moderately cellular loose fragments of tumor cells which had uniform round nuclei, small nucleoli, fine granular chromatin and moderate amount of cytoplasm. Plasmacytoid cells and binucleate forms were seen with a perivascular arrangement and the cells were positive for synaptophysin and chromogranin on Immunohistochemistry (IHC) with a Ki67 proliferation index of 1%. As a result, a diagnosis of grade I neuroendocrine tumor was given (Figure 1 and 2).

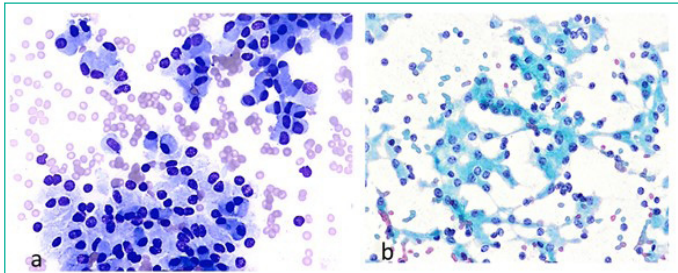


Figure 1: a) Loose aggregates of monomorphic tumor cells with eccentric nuclei. MGG stain, x200. b) Salt and pepper chromatin of tumor cells, Pap stain, x100.

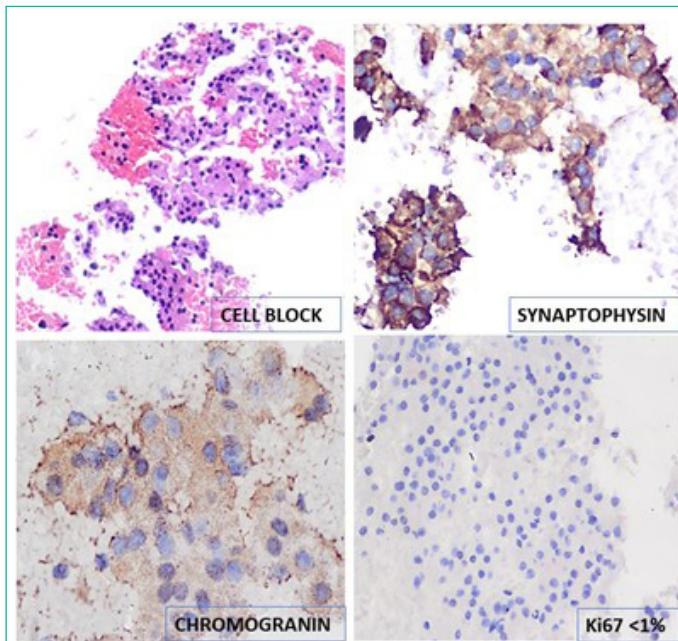


Figure 2: Cell block (H&E stain) and immunohistochemistry.

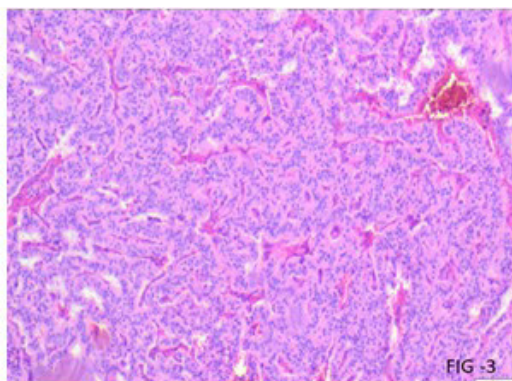


Figure 3: Tumor cells arranged in gyriform and trabecular pattern. Haematoxylin and Eosin stain. Magnification-200.

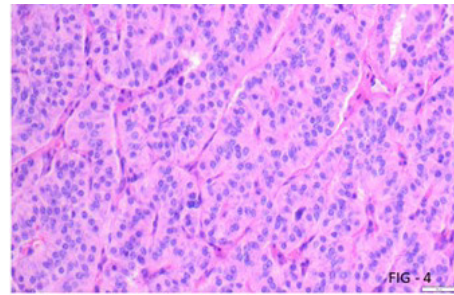


Figure 4: Tumour cells exhibiting salt and pepper chromatin, minimal atypia and absent mitosis. Haematoxylin and Eosin stain. Magnification - 400.

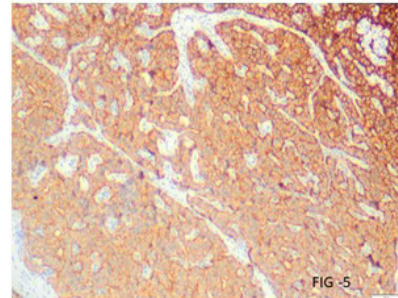


Figure 5: Tumour cells showing cytoplasmic positivity for synaptophysin: Immunoperoxidase stain. Magnification - 100.

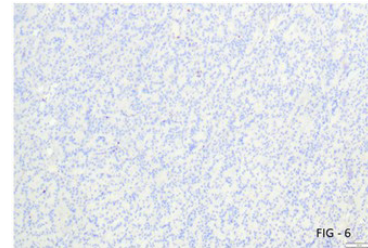


Figure 6: Ki67 labeling indicating low proliferative index. Immunoperoxidase stain. Magnification - 100.

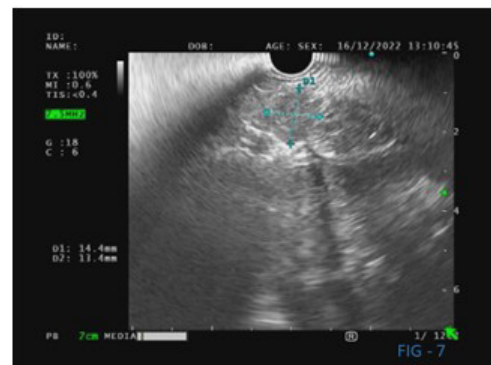


Figure 7: Endoscopic ultrasound revealing a well-defined hypoechoic space-occupying lesion near the pancreatico-duodenal groove.

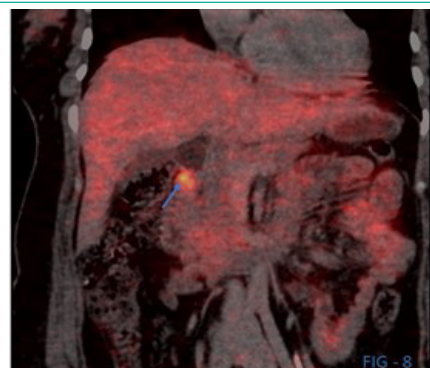


Figure 8: DOTA NOC PET CT (arrow) revealing a somatostatin receptor positive tumor in the pancreatico-duodenal groove.

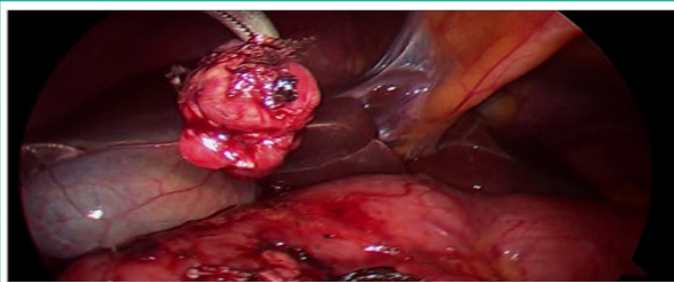


Figure 9: Enucleated tumor approximately 2x1 cm found near the pancreaticoduodenal groove.

A whole-body 68 Gallium (1,4,7,10-tetraazacyclododecane-1,4,7,10-tetraacetic acid NaI³-octreotide) DOTA NOC PET CT scan was done to check for metastasis (if any) revealed a solitary a somatostatin receptor positive tumor near the pancreatico-duodenal groove (Figure 8).

Less than 10% of pancreatic neuroendocrine tumors are associated with MEN 1 [1] and about 4 % of insulinomas are associated with MEN 1. Since the patient both clinically and on investigation, did not reveal any other endocrinal abnormality, the genetic test to confirm MEN 1 was not done.

She underwent a laparoscopic enucleation of a 2x1 cm NET and the tumor sent for frozen section. Histopathological findings were consistent with a neuroendocrine tumor (Figure 3-6). Patient was stable post-procedure and was discharged. She has not reported any recurrence of episodes on follow-up.

Discussion

Insulinoma is a rare functional neuroendocrine tumor and the most common cause of EHH [12]. Extra-pancreatic insulinoma has an incidence of about 2% with most of them in proximity to the duodenal wall [9] with most being <2 cm in diameter [8-11].

Zhang et al in their review have reported cases in which the tumor was found near the duodenum, duodeno-hepatic ligament, pelvis, jejunum etc. with most of them near the duodenal wall [13]. In our case the tumor was found in the pancreaticoduodenal groove.

Pre-operative localisation of insulinoma helps in reducing mortality and morbidity associated with insulinoma. CT being a simple non-invasive procedure and widely available is used first line to localise insulinomas. However, due to sensitivity which ranges from 33 -64% (for CT) the use of MRI is becoming popular. Recent studies [13-16] have advocated for the use of MRI for detecting insulinomas due to superior sensitivity and detection rates. The triple phase MRI can localise these tumors and metastases (if any) with great accuracy. In our case, MRI could not locate the tumor.

Endoscopic Ultrasound (EUS) has superior sensitivity for pancreatic neuroendocrine tumors as compared to CT or MRI and detect lesions as small as 2-5 mm [1]. Rosch et al [17] were the first to advocate for the use of EUS in detecting NETs. It has now become a standard test due to high detection rates [12,18-19] and proven high sensitivity and specificity [18]. Its applicability in obtaining a biopsy also makes it a preferred test. However, it is important to note that the sensitivity of EUS for insulinomas is contingent on the location and size of the tumor. For tumors in the head of the pancreas, sensitivity is high and for those in the tail of the pancreas and extra-pancreatic, it is low [5]. In terms of size, for tumors less than or equal to 2 cm in size, the

detection becomes challenging and is dependent on operator skill and experience [5]. In our case, the tumor was localised to the pancreaticoduodenal groove by the EUS.

The DOTA NOC PET/CT scans a high positive and negative predictive value for detecting neuroendocrine tumors. Due to the presence of Somatostatin Receptors (SSTR) especially SSTR-2 and SSTR-5 in majority of cases of insulinoma, this test has good applicability in terms of isolating insulinoma [20] and tracing metastasis (if any). In our case a somatostatin receptor positive tumor was seen at the pancreaticoduodenal groove.

For benign insulinoma, surgical excision is curative which was achieved via laparoscopic enucleation.

There were some limitations in this case. A 72-hour-fast could not be completed as the patient could not tolerate the test and was which could explain the normal value of C-peptide (4.87 ng.ml). Insulinoma exhibit over-expression of Glucagon Like Peptide 1 Receptor (GLP-1R). Therefore, a 68 Ga-Exendin-4 PET/CT, in which a synthetic GLP-1R radionuclide named exendin-4 is utilised as a tracer can diagnose insulinoma with higher accuracy and specificity [13], was not done due to non-availability of the test.

References

- Ishii T, Katanuma A, Toyonaga H, Chikugo K, Nasuno H, Kin T, et al. Role of endoscopic ultrasound in the diagnosis of pancreatic neuroendocrine neoplasms. *Diagnostics (Basel)*. 2021; 11: 316.
- Moldow RE, Connelly RR. Epidemiology of pancreatic cancer in Connecticut. *Gastroenterology*. 1968; 55: 677-86.
- Service FJ, McMahon MM, O'Brien PC, Ballard DJ. Functioning insulinoma--incidence, recurrence, and long-term survival of patients: a 60-year study. *Mayo Clin Proc*. 1991; 66: 711-9.
- Grant CS. Insulinoma. *Best Pract Res Clin Gastroenterol*. 2005; 19: 783-98.
- Sotoudehmanesh R, Hedayat A, Shirazian N, Shahraeni S, Ainechi S, Zeinali F, et al. Endoscopic ultrasonography (EUS) in the localization of insulinoma. *Endocrine*. 2007; 31: 238-41.
- R. Doi R, Komoto I, Nakamura Y, Kawamura J, Fujimoto K, Wada M et al. Pancreatic endocrine tumor in Japan. *Pancreas*. 2004; 28: 247-52.
- Mittendorf EA, Liu YC, McHenry CR. Giant insulinoma: case report and review of the literature. *J Clin Endocrinol Metab*. 2005; 90: 575-80.
- Kondo T, Tomita S, Adachi H, Motoshima H, Taketa K, Matsuyoshi A, et al. A case of hyperinsulinemia of undetermined origin, successfully treated with long-acting octreotide. *Endocr J*. 2005; 52: 511-7.
- Oberg K, Eriksson B. Endocrine tumours of the pancreas. *Best Pract Res Clin Gastroenterol*. 2005; 19: 753-81.
- Rostambeigi N, Thompson GB. What should be done in an operating room when an insulinoma cannot be found? *Clin Endocrinol (Oxf)*. 2009; 70: 512-5.
- Whipple AO, Frantz VK. Adenoma of islet cells with hyperinsulinism: a review. *Ann Surg*. 1935;101(6):1299-335.
- Service FJ. Diagnostic approach to adults with hypoglycemic disorders. *Endocrinol Metab Clin North Am*. 1999; 28: 519-32.vi.
- Zhang X, Jia H, Li F, Fang C, Zhen J, He Q, et al. Ectopic insulinoma diagnosed by 68ga-Exendin-4 PET/CT: A case report and review of literature. *Med (Baltim)*. 2021; 100: e25076.

14. Noone TC, Hosey J, Firat Z, Semelka RC. Imaging and localization of islet-cell tumours of the pancreas on CT and MRI. *Best Pract Res Clin Endocrinol Metab.* 2005; 19: 195-211.
15. McAuley G, Delaney H, Colville J, Lyburn I, Worsley D, Govender P, et al. Multimodality preoperative imaging of pancreatic insulinomas. *Clin Radiol.* 2005; 60: 1039-50.
16. Anaye A, Mathieu A, Closset J, Bali MA, Metens T, Matos C. Successful preoperative localization of a small pancreatic insulinoma by diffusion-weighted MRI. *JOP.* 2009; 10: 528-31.
17. Rösch T, Lightdale CJ, Botet JF, Boyce GA, Sivak MV, Yasuda K, et al. Localization of pancreatic endocrine tumors by endoscopic ultrasonography. *N Engl J Med.* 1992; 326: 1721-6.
18. Puli SR, Kalva N, Bechtold ML, Pamulaparthi SR, Cashman MD, Estes NC, et al. Diagnostic accuracy of endoscopic ultrasound in pancreatic neuroendocrine tumors: a systematic review and meta analysis. *World J Gastroenterol.* 2013; 19: 3678-84.
19. Kim MK. Endoscopic ultrasound in gastroenteropancreatic neuroendocrine tumors. *Gut Liver.* 2012; 6: 405-10.
20. Li TN, Liu Z, Zhang Y, Wang F. Ectopic insulinomas in the pelvis secondary to rectum neuroendocrine tumour. *BMJ Case Rep.* 2018; 2018: bcr2018224281.