

Review Article

Guided Soft Tissue Regeneration with Three-Dimensional Matrices: A Novel Technique to Enhance Volume Around Implants

De Annuntiis C*

Department of Dentistry, Private Perio-Implant Practice, Rome

***Corresponding author:** Carlo De Annuntiis, Department of Dentistry, Private Perio-Implant Practice, Rome**Received:** June 21, 2022; **Accepted:** July 27, 2022;**Published:** August 03, 2022**Abstract**

In recent years, the attention to the soft tissue is growing because both the clinicians and the patients have understood they are crucial in achieving not just a good aesthetic but furthermore a long stability of the underlying bone. Until less than a decade ago, the only one way to manage periodontal or peri-implant soft tissue was with autologous connective tissue harvested from the palate or from the tuberosity. Nowadays, several substitutes derived from animal allow to avoid a second surgery to obtain connective tissue. The present manuscript presents a new approach to the modern implantology in order to achieve better outcomes from an aesthetic and functional point of view using a new porcine derived matrix. The manuscript shows either a step by step description of a novel technique to enhance soft tissue around implants.

Introduction

During the last four decades of implantology, the scientific literature has focused on bone and his behavior around implants. Thanks to a huge quantity of publications, nowadays, we know very well the relationship between bone and implant from the extraction of the tooth to the placement of the fixture and during the integration process and the follow-up time [1-5]. The procedures of Guided Bone Regeneration (GBR) became a predictive procedure to ensure a long healthy life for the implant [6,7].

In recent years, the attention has switched to the soft tissue because both the clinicians and the patients have understood they are crucial in achieving not just a good aesthetic but furthermore a long stability of the underlying bone.

The present paper presents a novel technique to regenerate volume around implants enhancing soft tissue with a three-dimensional matrix derived from porcine.

Materials and Methods

A new acellular dermal matrix (NovoMatrixTM; LifeCell, Branchburg, NJ, USA) which consisted of tissue-engineered porcine material was used. Owing to the manufacturing process, this matrix is free of donor cells. At the same time, the structure of the source tissue remains virtually unchanged, thus supporting the ingrowth of cells and micro-vessels. Indeed, the process preserves many proteins, molecules and vessels: first of all, vascular channels are kept in order to provide a quick blood flow throughout the matrix enabling the first phases of revascularization; collagen is left to provide structure and tensile strength, elastin to ensure elasticity, hyaluronan to control tissue hydration, proteoglycans to guide revascularization and cell repopulation and fibronectin which is responsible for cell adhesion, migration, growth and differentiation.

Because of this preserved structure, the matrix seems to have a bio-potential in being grafted to a donor site and in order to achieve

the best behavior from this matrix, the Author suggests always raising a split thick flap. In this way, it is possible to ensure to the matrix a double vascularization both from the inner side and from the covering flap. The aim of this novel technique is to recreate the typical convexity of a natural tooth even at implant side not recurring massive and more aggressive procedures of bone regeneration. Hence, the only requirement is having the proper bone support to fully cover the implant. Once the implant is correctly placed it is therefore possible to recreate the lack of volume using the following technique with a great advantage in terms of shorter chair-time, less compliance and after-effects for the patient, easier learning curve for the clinician and a very fast healing process.

The technique leads to the formation of a new thicker and stable amount of soft tissue, naming it GSTR which stands for Guided Soft Tissue Regeneration.

The amount of volume that can be regenerated depends on the number of layers of matrix used in each specific situation, considering that the matrix has a constant thickness of 1mm. In the Author's experience soft tissue regenerations are frequent with double or triple layers: several data about the gain of volume and its stability over time will be shown in the Results paragraph.

The step-by-step procedure is described in the following points and it is applicable in all the clinical situations in which there is enough bone to place a prosthetically driven implant completely surrounded by bone.

Raising the flap

As previously suggested, raising a split thickness flap allows us to keep periosteum and muscular insertion in order to maintain peristal vascularization of the bone and furthermore to have soft tissue available to suture the matrix. The first incision is not right in the middle of the crest but slightly moved towards the inner side in order to raise just the vestibular flap keeping stable the inner flap and so having the opportunity to suture the matrix on it either.

Preparing and placing the implant

The preparation and the insertion of the implant proceed in the common way with the only difference that instead of a “white” bone without periosteum we drill a “red” bleeding bone completely covered by its periosteum. If the primary torque of insertion is 25N or more, a healing abutment either in titanium or in peek is placed to cover the implant.

Cutting and placing the matrix

The matrix is now taken out of its packaging and it is already wet and ready to be used. The clinician can now decide the length and the depth of the needed shape and cut it with a novel scalpel giving to the matrix the most suitable form.

Using more layers of the matrix: the inlay technique

If the lack of volume around the implant is too much to be handled by just one layer of matrix, it is possible to suture more layers to each other enhancing the thickness of the graft. The Author purposes an Inlay Technique which gives the layers the correct shape to fill the lack of volume of each specific clinical situation. It is therefore possible to have different shapes of multiple layers sutured to each other in one unique inlay graft ready to be placed on the bleeding bed around the implant and fixed to the periosteum and/or to the flap.

Suturing the flap

Although left minimally exposed the matrix could work if the maximum part of it is covered by the flap, the Author strongly suggests covering completely the matrix ensuring a double vascularization as in a bilaminar technique. The double vascularization is essential in those situations in which the graft is made with double or triple layers

in order to guarantee to both side of the graft the opportunity of a quick integration with the surrounding tissue.

Results

To assess the efficacy of the technique in terms of gain of volume and stability, a multicentric trial was designed and the collected data will be presented in another publication in which there will be described specifically what measurements were taken and for how long the augmented tissue was tested. Here is useful to underline that either in single or multiple layer procedures, the linear augmentation is thicker than the thickness of the used layers. The volume reached at the end of the surgery continues to grow during the first three months with a slight contraction between the 3rd and 6th months, remaining stable for the last 6 months of observation, after 1 year of follow-up.

Discussion

In recent years, soft tissue grafting has become a topic of growing interest in implant dentistry. The proposed surgical procedures aim mainly at increasing both the width of keratinized tissue and the soft tissue volume at dental implant sites to improve functional, aesthetic, and biological outcomes after therapy [8].

Various procedures and different materials were assessed in the recent past to augment keratinized tissue around implant [8-10] and every Author concluded that soft tissue grafting procedures result in biologic benefits. Nevertheless, data from recent systematic reviews [11-13] are more controversial and not fully able to support these surgical procedures to maintain or enhance peri-implant health, so the predictive value of keratinized mucosa is limited. Despite the Literature failing to support that the lack of keratinized mucosa

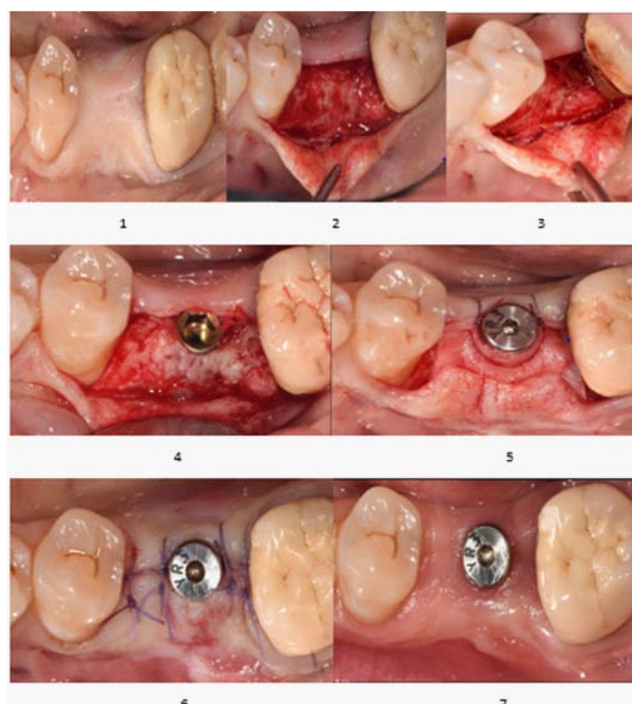


Figure 1: SINGLE- layer use of the Matrix.

(1) Initial situation (2) Split thickness flap raised (3) Split thickness flap raised; different view to show the muscle insertion (4) Implant placed (5) The matrix, placed around the collar of the implant, was sutured to the inner flap (6) The flap closed for primary intention (7) Guided soft tissue regeneration on the buccal side at 7 weeks, ready to start the prosthetic procedures.

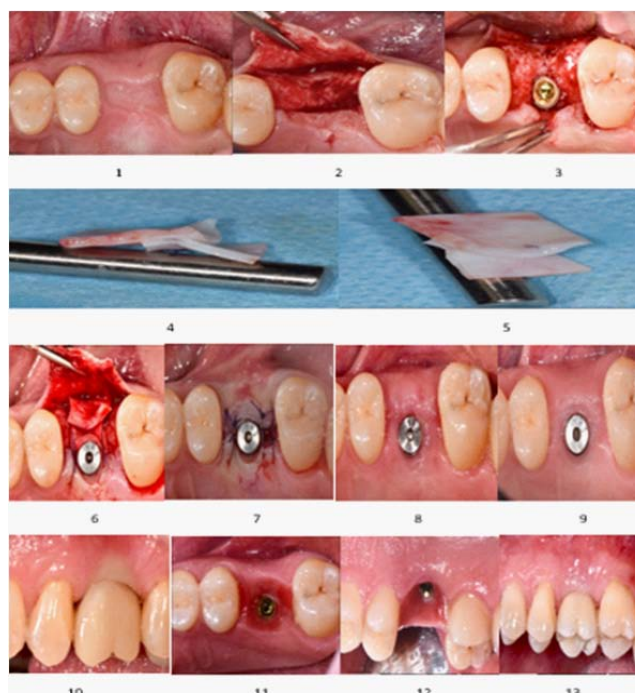


Figure 2: DOUBLE-layer use of the Matrix.

(1) Initial situation. Lack of buccal volume (2) Split thickness flap raised (3) Implant placed (4) An inlay of connective tissue was built with two layers of the Matrix (5) An inlay of connective tissue was built with two layers of the Matrix: different view (6) The inlay of Matrix placed and sutured (7) The flap was sutured for primary intention (8) Two weeks later: sutures removing (9) GSTR at 2 months of healing and maturation (10) Provisional crown working on the regenerated soft tissue (11) Healthy and compact tissue after provisional crown conditioning (12) The inner side of the regenerated tissue: presence of blood vessels with no sign of inflammation (13) The final ceramic crown.

could jeopardize the maintenance of soft tissue health around implants, it's a common belief amongst clinicians that the more KM around implant the more soft tissue health. To understand better this difference between the data from Literature and the clinical perception, the scientific papers have to be analyzed closer in the way the data was collected. Indeed, the Studies that suggested that the need for KM around implant is limited [14,15] collected data from patients in a very rigid maintenance of oral hygiene, underlying the concept that in case of very good compliant patients the role of KM is less important in obtaining healthy perimplant tissue. On the contrary, the Publication from Monje and Blazi, 2019 [16], analyzing the significance of KM in the erratic maintenance compliers (<2times/year) concluded that all the clinical and radiographic parameters worsened for reduced KM.

An interesting field to be investigated is the aesthetic perception from the patient in both situations with or without a proper band of KM around implant supported crown. Bonino [17] in 2018 noted that patients reported a greater satisfaction with the esthetics of implants with larger KM. Similar outcomes was by Cairo [18], 2017 that in his randomized controlled clinical trial assessed CTG and Xenogenic Matrix in managing soft tissue around implants, confirming all treated patients were highly satisfied in terms of final aesthetic outcomes. However, it's also confirmed a longer chair- time (16 minutes more) and greater morbidity for the CTG group, as demonstrated in previous publications [19,20].

Interestingly, when assessing overall satisfaction, higher VAS

values were reported for the Matrix group than controls, thus supporting the detrimental effect of harvesting procedure on patient opinion [21].

The large amount of tissue that can be recreated by using multiple layers of tridimensional Matrix has been shown by De Annuntiis [22], 2022 using up to three layers due to the clinical situation.

The absence of periodontal ligament, root cementum, and connective tissue attachment around dental implants may make peri-implant tissues more susceptible to the development of a robust inflammatory response with following bone loss [23]. Linkevicius et al. [24] performed clinical controlled study and found that implants with mucosal tissues of 2 mm or less in thickness may have greater bone loss than implants placed in thicker tissues. Starting from this evidence, Puisys and Linkevicius [25] performed a prospective controlled new trial assessing the bone loss around implants with different thickness of soft tissue phenotype. They identified three groups: thick, when the thickness was 2mm or more; thin, when the thickness was less than 2mm; thickened when a thin phenotype was augmented by a matrix. The outcomes showed as the thickened tissues responded as the thicker phenotype losing around 0.2mm of bone *versus*. 1.2mm of bone loss of the thinner phenotype group.

Conclusion

At the time this manuscript was written, the GSTR technique had been performing for a couple of years in over 60 situations with excellent clinical outcomes and very limited patient morbidity. With

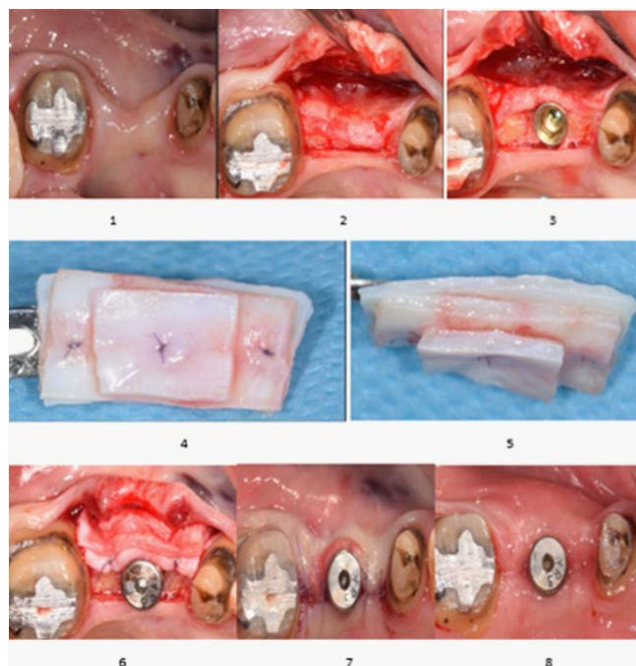


Figure 3: TRIPLE-layer use of the Matrix.

(1) Initial situation: huge lack of buccal volume (2) Split thickness flap: the whole periosteum has been left covering the buccal bone (3) Implant placed entirely in native bone (4) Three layers of the Matrix were sutured each other (5) The three-layer inlay of Matrix in a different view (6) The inlay was sutured to the inner flap (7) The flap was closed for primary intention (8) GSTR at 2 months, starting the prosthetic procedures.

all the limitations of this single publication, this novel approach resulted effective. These outcomes should be assessed and confirmed in larger future studies.

References

- Cardaropoli G, Araújo M, Lindhe J. Dynamics of bone tissue formation in tooth extraction sites. An experimental study in dogs. *J Clin Periodontol*. 2003; 30: 809-818.
- Araujo MG & Lindhe J. Dimensional ridge alterations following tooth extraction. An experimental study in dog. *J Clin Periodontol*. 2005; 32: 212-218.
- Trombelli L, Farina R, Marzola A, Bozzi L, Liljenberg B, Lindhe J. Modeling and remodeling of human extraction sockets. *J Clin Periodontol*. 2008; 35: 630-639.
- Discepoli N, Vignoletti F, Laino L, De Sanctis M, Munoz F, Sanz M. Early healing of the alveolar process after tooth extraction: an experimental study in the beagle dog. *J Clin Periodontol*. 2013; 40: 638-644.
- Araujo MG, Silva CO, Misawa M, Sukekava F. Alveolar socket healing: what can we learn? *Periodontol*. 2015; 68: 122-134.
- Wessing B, Lettner S, Zechner W. Guided Bone Regeneration with Collagen Membranes and Particulate Graft Materials: A Systematic Review and Meta-Analysis. *Int J Oral Maxillofac Implants*. 2018; 33: 87-100.
- Garcia J, Dodge A, Luepke P, Wang HL, Kapila Y, Lin GH. Effect of membrane exposure on guided bone regeneration: A systematic review and meta-analysis. *Clin Oral Implants Res*. 2018; 29: 328-338.
- Thoma DS, Buranawat B, Hämmerle CH, Held U, Jung RE. Efficacy of soft tissue augmentation around implants and in partially edentulous areas: a systematic review. *J Clin Periodontol*. 2014; 41: 77-91.
- Thoma DS, Benić GI, Zwahlen M, Hämmerle CH, Jung RE. A systematic review assessing soft tissue augmentation techniques. *Clin Oral Implants Res*. 2009; 20: 146-165.
- Cairo F, Barbato L, Selvaggi F, Baielli MG, Piattelli A, Chambrone L. Surgical procedures for soft tissue augmentation at implant sites. A systematic review and meta-analysis of randomized controlled trials. *Clin Implant Dent Relat Res*. 2019; 21: 1262-1270.
- Lin GH, Chan HL, Wang HL. The significance of keratinized mucosa on implant health: a systematic review. *J Periodontol*. 2013; 84: 1755-1767.
- Gobbato L, Avila-Ortiz G, Sohrabi K, Wang CW, Karimbux N. The effect of keratinized mucosa width on peri-implant health: a systematic review. *Int J Oral Maxillofac Implants*. 2013; 28: 1536-1545.
- Brito C, Tenenbaum HC, Wong BK, Schmitt C, Nogueira-Filho G. Is keratinized mucosa indispensable to maintain peri-implant health? A systematic review of the literature. *J Biomed Mater Res B Appl Biomater*. 2014; 102: 643-650.
- Wennström JL, Bengazi F, Lekholm U. The influence of the masticatory mucosa on the peri-implant soft tissue condition. *Clin Oral Implants Res*. 1994; 5: 1-8.
- Wennström JL, Derks J. Is there a need for keratinized mucosa around implants to maintain health and tissue stability? *Clin Oral Implants Res*. 2012; 23: 136-146.
- Monje A, Blasi G. Significance of keratinized mucosa/gingiva on peri-implant and adjacent periodontal conditions in erratic maintenance compliers. *J Periodontol*. 2019; 90: 445-453.
- Bonino F, Steffensen B, Natto Z, Hur Y, Holtzman LP, Weber HP. Prospective study of the impact of peri-implant soft tissue properties on patient-reported and clinically assessed outcomes. *J Periodontol*. 2018; 89: 1025-1032.
- Cairo F, Barbato L, Tonelli P, Batalocco G, Pagavino G, Nieri M. Xenogenic collagen matrix versus connective tissue graft for buccal soft tissue augmentation at implant site. A randomized, controlled clinical trial. *J Clin Periodontol*. 2017; 44: 769-776.
- Cairo F, Pagliaro U, Nieri M. Soft tissue management at implant sites. *J Clin Periodontol*. 2008; 35: 163-167.
- Cairo F, Nieri M, Pagliaro U. Efficacy of periodontal plastic surgery procedures in the treatment of localized facial gingival recessions. A systematic review. *J Clin Periodontol*. 2014; 41: 44-62.

21. McGuire MK, Nunn M. Evaluation of human recession defects treated with coronally advanced flaps and either enamel matrix derivative or connective tissue. Part 1: Comparison of clinical parameters. *J Periodontol.* 2003; 74: 1110-1125.
22. De Annuntiis C, Testarelli L, Guarnieri R. Use of Xenogenic Collagen Matrices in Peri-Implant Soft Tissue Volume Augmentation: A Critical Review on the Current Evidence and New Technique Presentation. *Materials.* 2022; 31: 3937.
23. Abrahamsson I, Soldini C. Probe penetration in periodontal and peri-implant tissues. An experimental study in the beagle dog. *Clin Oral Implants Res.* 2006; 17: 601-605.
24. Linkevicius T, Apse P, Grybauskas S, Puisys A. The influence of soft tissue thickness on crestal bone changes around implants: a 1-year prospective controlled clinical trial. *Int J Oral Maxillofac Implants.* 2009; 24: 712-719.
25. Puisys A, Linkevicius T. The of mucosal tissue thickening on crestal bone stability around bone-level implants. A prospective controlled clinical trial. *Clin Oral Implants Res.* 2015; 26: 123-129.