

Case Report

Screw-Retained Implant-Supported Fixed Dental Restorations: A Rational Method to Overcome Esthetic Issues with the Screw-Access Hole

Etienne O^{1*}, Waltmann E² and Serfaty R³

¹Head of Prosthodontics Department, School of Dental Medicine, University of Strasbourg, France

²Assistant Professor, Prosthodontics Department, School of Dental Medicine, University of Strasbourg, France

³Assistant Professor, Restorative Department, School of Dental Medicine, University of Strasbourg, France

*Corresponding author: Olivier Etienne, Head of Prosthodontics Department, School of Dental Medicine, University of Strasbourg, 1, Place de l'Hopital, 67000 Strasbourg, France

Received: June 07, 2021; Accepted: July 09, 2021;

Published: July 16, 2021

Abstract

Achieving both esthetics and a perfect seal of the screw-access hole in a screw-retained implant-supported fixed dental restoration is a great challenge. From a functional point of view, a perfect seal needs to be obtained to prevent bacterial contamination along the screw access canal and the occlusion shall be addressed. Such a challenging procedure has to be based on a rational analysis of the different materials used. Screw-retained zirconia-based restorations offer a new perspective for esthetic and biocompatible results. The aim of this article is to describe an easy and reproducible clinical procedure to esthetically seal the screw-access hole of screw-retained implant-supported fixed dental restorations.

Keywords: Esthetics; Zirconia; Clinical procedure; Filling; Screw-access hole

Introduction

Whether using a screw-retained versus a cement-retained implant-supported fixed dental restorations is still a complex decision involving many clinical and mechanical considerations [1-3]. Often, decision-making is primarily driven by the visibility of the screw-access hole and it's the poor final esthetic outcome [4,5].

In fact, the classical clinical options were based on Porcelain-Fused-to Metal Dental Crowns (PFM crowns) resulting in many difficulties to mask the grey aspect of the metal part around the occlusal opening screw access (Figure 1).

Up to now, only a few methods have been described in the literature to achieve a better esthetic result. Mostly, they were based on the addition of an opaquer layer [5] or a dentin shade composite resin [6]. Unfortunately, these attempts were only part of the solution. In fact, in order to hide the metal shadow, Kim et al. demonstrated that a 1 to 2 mm-thick opaque shade composite needed to be placed [7]. A real esthetic result seems to be compromised when working with screw-retained metal-core materials, unless an important occlusal reduction of the abutments is made.

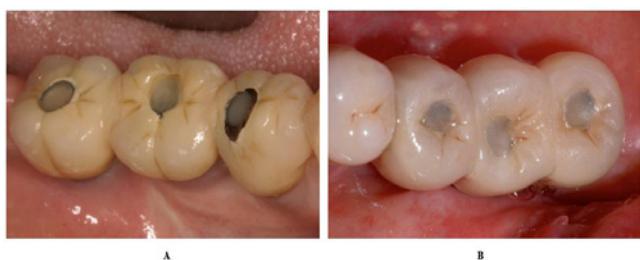

Figure 1: Poor esthetic result was obtained with metal-ceramic screw-retained implant bridges. Depending on the thickness of the layering ceramic, the esthetic result varied from black (A) to grey (B).

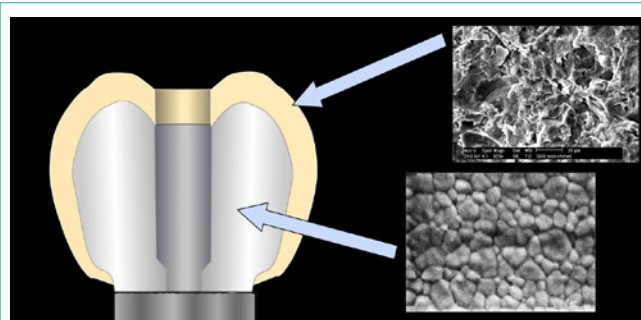


Figure 2: Zirconia based screw-retained implant crown is a bilayered construction. The layering ceramic is a glass ceramic whereas the framework is an oxide ceramic. SEM images on the right show the structure of the two different materials (upper: feldspar ceramic, lower: zirconia): the upper one can be successfully etched, whereas the lower one cannot.

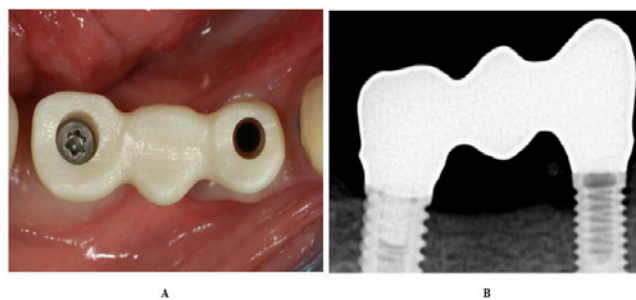


Figure 3: The passive fit of the zirconia framework (NobelProcera Zirconia®) must be controlled first (e.g. Sheffield test). The design of the framework should manage a constant veneering ceramic thickness.

As an alternative, frameworks made of Zirconia are available for screw-retained solutions on implants since 2002 (Procera Zirconia, Nobelbiocare). They can be used either for single-unit crown or

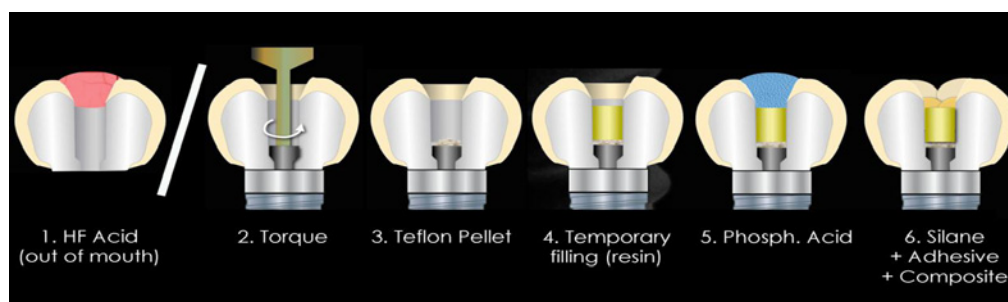


Figure 4: Schematic cross-section of access canal showing the clinical procedure step-by-step. 1) Hydrofluoric (HF) acid etching of the feldspar ceramic layer (out of the mouth); 2) Final screw torque applying; 3) Protection of the screw head (Teflon pellet); 4) Filling with a resilient material (temp filling single-component resin); 5) Phosphoric acid cleaning of the feldspathic ceramic layer; 6) Silanization; 7) Adhesive coating; 8) Polymerization of the adhesive; 9) Filling of the canal with a resin composite (stratified layering technique); 10) Polishing.

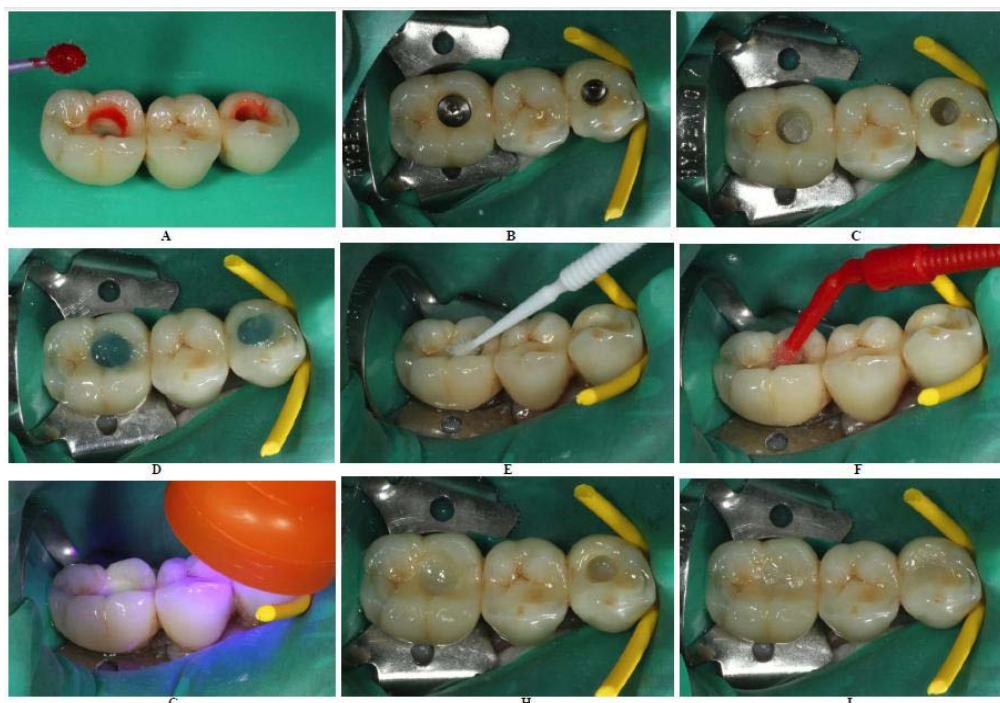


Figure 5: A) Outside of the oral cavity, the inner part of the access opening is etched with the hydrofluoric acid (IPS Ceramic Etching Gel, Ivoclar-Vivadent) for 120 seconds as recommended for feldspar ceramic. Then, the HF acid gel is thoroughly rinsed with water and dried with the air syringe. B) The bridge is first screwed by hand before installation of the rubber dam. Then, the screws are torqued to 30Ncm, as recommended by the manufacturer. C) A cotton pellet is placed upon the retention screw heads in a thin layer and covered by a harder material (Telio Inlay®, Ivoclar-Vivadent). This last is polymerized and offers a rigid base for the upper layers, while being easily retrievable. D) The phosphoric acid gel is used as a cleaning gel for 30sec, rinsed off air-dried with the air syringe. E) The silane agent (Monobond-Plus) is applied to the inner aspects of the canal for 180 seconds and air-dried. F) The canal is then coated with the bonding agent (Excite, Ivoclar-vivadent), using a microbrush that is thoroughly applied to the inner part of the access holes. G) Photopolymerization of the bonding agent (20sec) is the last step before filling of the last part of the access opening. H) Layers of dentin shade composite are then built up on a cusp-by-cusp basis, polymerizing each cusp individually in order to reduce the 'Configuration factor' of the restoration and therefore the polymerization stress. I) As an option, tints can be sparingly applied at this stage to enhance the characterization of the occlusal fissures. Finally, the enamel shade layers are placed and polymerized on the same cusp-by-cusp strategy.

multi-unit bridge and are available in various shades. In a previous study, we have shown that these constructions, linking a zirconia abutment to a titanium implant, present a reduced microgap when assembled [8].

The zirconia framework is veneered with a glass ceramic to obtain the final morphology and esthetics, therefore creating a bilayered material with specific properties for each layer (Figure 2). These properties should be considered especially when trying to achieve a

better sealing of the occlusal screw access.

Case Presentation

Once passiveness of the framework has been clinically validated (Figure 3), the final layering can be carried out in a lab setting.

At the following appointment, the inter-proximal and occlusal contacts are adjusted, and esthetic is validated before the final insertion of the restoration takes place, following an easy step-by-step procedure (Figure 4).

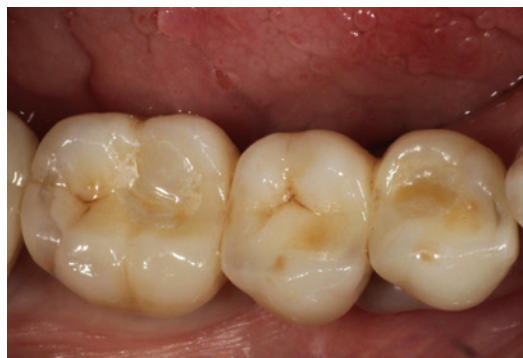

Figure 6: The occlusion is checked. Minimal adjustments should be made to preserve the enamel layer. A final polishing is then carried out.

The layering glass ceramic needs to be prepared first to enhance the bond strength and consequently the sealing efficiency. Etching with Hydrofluoric (HF) acid followed by application of a silane coupling agent has been mainly described as the best procedure to successfully prepare glass ceramic surfaces [9,10]. HF acid attacks the glass matrix of the ceramic, producing a micromechanical retentive surface, and the silane-coupling agent promotes a chemical bond between the inorganic glass phase and the organic matrix of the resin cement. Due to severe damage risks, the use of HF is prohibited in the oral cavity. Hence, HF must be applied previously to the final insertion: feldspar ceramic usually used as layering ceramic must be etched for 2 minutes [11], thoroughly rinsed and air-dried. The Sodium bicarbonate neutralization, classically described, appears to be dispensable when the rinse is well-controlled [12].

Once properly etched, the restoration can be inserted and screwed to the final torque (Figure 5A). The head of the screw has to be covered with a soft material, such as a Teflon pellet (Figure 5B), to enable further retrievability. Caution should be used to keep this layer to a minimal thickness to prevent any further risk of sinking the upper laying materials during occlusion. A resilient composite, such as the temporary filling material Telio inlay® (Ivoclar-Vivadent), can then be applied over the Teflon pellet and cured (Figure 5C). Then, the inner glass ceramic surfaces that had been contaminated during these first steps should be cleaned with phosphoric acid before the final sealing (Figure 5D).

The Silane coupling agent is first applied spread and evaporated (3min). Then, the bonding agent is carefully applied in the inner walls of the access holes, spread and cured. Finally, the composite resin material is placed, using the stratified layering technique (Figure 5E-5G). In fact, bulk filling a canal is the worst situation for the Configuration factor and result in a maximal shrinkage stress.

Therefore, the resin composite should be modeled and cured by addition of small amounts on the different walls of the canal (Figure 5H and 5I).

Furthermore, in order to improve the final esthetic outcome, pits and fissures can be stained using a flowable characterization material for direct composite (e.g. Tetric Color®, Ivoclar-Vivadent). After the occlusal adjustments, the final polishing gives a realistic and biomimetic result (Figure 6).

Conclusion

Screw-retained implant-supported fixed dental restorations may benefit from an esthetic framework when using zirconia-based core material. Efforts should be made to follow a strict clinical procedure when filling screw-access holes in order to achieve an esthetic result with a minimal risk of leakage.

References

1. Chee W, Felton DA, Johnson PF, Sullivan DY. Cemented versus screw-retained implant prostheses: which is better? *Int J Oral Maxillofac Implants.* 1999; 14: 137-141.
2. Chee W, Jivraj S. Screw versus cemented implant supported restorations. *Br Dent J.* 2006; 201: 501-507.
3. Lee A, Okayasu K, Wang HL. Screw- versus cement-retained implant restorations: current concepts. *Implant Dent.* 2010; 19: 8-15.
4. Vigolo P, Givani A, Majzoub Z, Cordioli G. Cemented versus screw-retained implant-supported single-tooth crowns: a 4-year prospective clinical study. *Int J Oral Maxillofac Implants.* 2004; 19: 260-265.
5. Weininger B, McGlumphy E, Beck M. Esthetic evaluation of materials used to fill access holes of screw-retained implant crowns. *J Oral Implantol.* 2008; 34: 145-149.
6. Taylor RC, Ghoneim AS, McGlumphy EA. An esthetic technique to fill screw-retained fixed prostheses. *J Oral Implantol.* 2004; 30: 384-385.
7. Kim SJ, Son HH, Cho BH, Lee IB, Um CM. Translucency and masking ability of various opaque-shade composite resins. *J Dent.* 2009; 37: 102-107.
8. Baixe S, Fauxpoint G, Arntz Y, Etienne O. Microgap between zirconia abutments and titanium implants. *Int J Oral Maxillofac Implants.* 2010; 25: 455-460.
9. Hooshmand T, van Noort R, Keshvad A. Bond durability of the resin-bonded and silane treated ceramic surface. *Dent Mater.* 2002; 18: 179-188.
10. Blatz MB, Sadan A, Kern M. Resin-ceramic bonding: a review of the literature. *J Prosthet Dent.* 2003; 89: 268-274.
11. Layton D, Walton T. An up to 16-year prospective study of 304 porcelain veneers. *Int J Prosthodont.* 2007; 20: 389-396.
12. Amaral R, Ozcan M, Bottino MA, Valandro LF. Resin Bonding to a Feldspar Ceramic after Different Ceramic Surface Conditioning Methods: Evaluation of Contact Angle, Surface pH, and Microtensile Bond Strength Durability. *J Adhes Dent.* 2010; 13: 551-560.