

Case Report

A Case of Rising Serum Ammonia Associated with Early Detection of Antibiotic Resistant *Pseudomonas Aeruginosa* Pneumonia

Pederson TG^{*}; Tainter CR

Department of Anesthesiology University of California San Diego Health, USA, thomasgpederson@gmail.com

***Corresponding author: Pederson TG**

Department of Anesthesiology University of California San Diego Health, USA, 200 W. Arbor Drive, #8829, San Diego, CA 92103, USA.

Tel: 303-949-8590

Email: thomasgpederson@gmail.com

Received: September 14, 2023**Accepted:** October 10, 2023**Published:** October 17, 2023

Introduction

Hyperammonemia is an important contributor to morbidity and mortality in the ICU setting. Hyperammonemia is commonly encountered in the ICU in association with primary liver pathologies, in which damaged or dysfunctional periportal hepatocytes are unable to adequately metabolize circulating ammonia produced by protein digestion, amino acid deamination, or bacterial urea metabolism, leading to increased serum

Abstract

Background: Hyperammonemia is frequently encountered in critical illness as a consequence of liver failure, but Nonhepatic Hyperammonemia (NHHA) can also occur in pathologies causing ammonia overproduction or inappropriate ammonia clearance. Sepsis-associated hyperammonemia is a subset of NHHA associated with urease producing infections causing ammonia overproduction.

Case Description: We report an unusual case of sepsis-associated NHHA secondary to multi-drug resistant *Pseudomonas aeruginosa* pneumonia in a 50-year-old critically ill man who was admitted to the intensive care unit for cardiogenic shock, respiratory failure, and hepatic failure secondary to myocardial infarction with papillary muscle rupture. He subsequently developed *P. aeruginosa* pneumonia and was treated empirically with piperacillin/tazobactam and subsequently meropenem as guided by culture data. The patient's serum ammonia concentration was incidentally trended to stratify risk for cerebral edema. Eight days into his pneumonia treatment course, the patient's serum ammonia level abruptly doubled despite improving hepatic function, which prompted switching the *P. aeruginosa* treatment from meropenem to ciprofloxacin. Bronchial washings later revealed that the *P. aeruginosa* had acquired resistance to meropenem. The patient subsequently demonstrated clinical improvement and also had a downward trend in the serum ammonia concentration. Another trend of hyperammonemia without worsening hepatic function later in his hospital course correlated with *P. aeruginosa* infection with acquired resistance to ciprofloxacin, and which improved with the addition of inhaled tobramycin to the antibiotic regimen.

Conclusions: In sepsis-associated NHHA, the serum ammonia trend may be a useful adjunct marker to indicate treatment response and provide an early indication of antibiotic treatment resistance.

Keywords: Nonhepatic hyperammonemia; Sepsis; Infection markers; Antibiotic resistance; Case report

Abbreviations: NHHA: Nonhepatic Hyperammonemia; UTI: Urinary Tract Infection; *P. aeruginosa*: *Pseudomonas Aeruginosa*

ammonia accumulation [1]. In a small subset of approximately 5% of ICU patients, hyperammonemia can also occur without hepatic injury, in a process referred to as nonhepatic hyperammonemia (NHHA) [1,2]. NHHA can result either from ammonia overproduction or from impaired ammonia clearance.

Sepsis-associated hyperammonemia is a subset of NHHA

which can be caused by direct disruption of ammonia metabolism, as well as by ammonia overproduction by urease-producing organisms [3]. *E. coli* intestinal tract and Urinary Tract Infections (UTIs) are most commonly cited in sepsis-associated NHHA [1,2,4]. However, the list of urease producing bacteria also includes *Proteus mirabilis*, *Morganelli morganii*, *Klebsiella spp.*, *Pseudomonas aeruginosa*, *diphtheroids*, *Escherichia coli*, and *Providencia rettgeri* [1]. Apart from intestinal tract infections and UTIs, these organisms can also cause bacteremia, endocarditis, wound infections, central nervous system infections, and pneumonia. The mechanism for sepsis-associated hyperammonemia is by hydrolysis of nitrogen-containing compounds into glutamine and ammonia, which are absorbed into the circulation. Additionally, hydrolysis of urea into ammonium in the urine also results in urine alkalization which promotes increased ammonia diffusion back into the bloodstream [2,5].

In critically ill patients with elevated serum ammonia not due to hepatic dysfunction, the consideration of infection with a urease-producing organism is recommended as part of the broader workup of NHHA [1]. However, to these authors' knowledge, observing the trend in serum ammonia concentration as an additional marker for antibiotic treatment efficacy against a known urease-producing organism has not been reported in the literature. Here, we present a case of a critically ill patient with *Pseudomonas aeruginosa* pneumonia and NHHA in which multiple rebounds of hyperammonemia were considered as an additional marker of acquired resistance to the current antibiotic therapy.

Case Presentation

The patient is a 50-year-old male with a past medical history of hypertension who presented with respiratory failure and cardiogenic shock, following delayed presentation of myocardial infarction with papillary muscle rupture and severe mitral regurgitation. The patient was intubated, had a drug eluting stent placed in the left circumflex artery, and had insertion of an Impella(r) device at an outside hospital on day 0. The patient was transferred to our hospital on day 3 of illness and underwent mitral valve replacement and one-vessel coronary artery bypass grafting of the posterior descending artery on day 5. His operative course was complicated by severe shock and multi-organ system failure, including persistent respiratory failure, acute renal failure, and hepatic failure. On day 6, the patient developed leukocytosis with peak WBC 60.7 k/mm³, attributed clinically to ventilator-associated pneumonia, and he was started on empiric vancomycin and piperacillin/tazobactam therapy. Serum ammonia concentration was first measured on day 7 to help stratify the risk for cerebral edema.

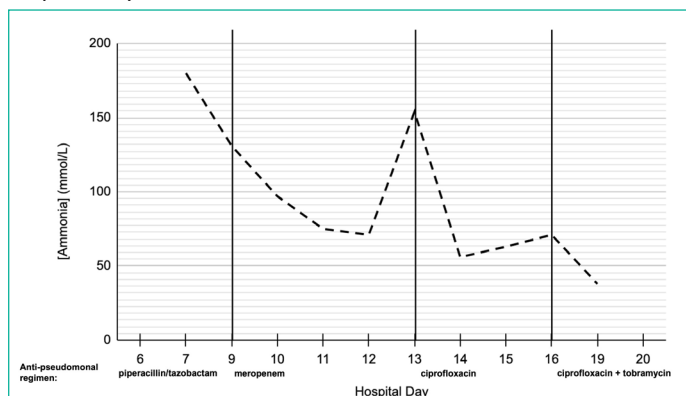


Figure 1: Serum ammonia concentration data by day of hospital admission. Vertical dividers on x-axis denote the anti-pseudomonal regimen for the range of hospital days.

Table 1: Susceptibility patterns for *Pseudomonas aeruginosa* obtained via tracheal aspirate results on hospital days 13 and 18. **Bolded** antibiotics denote all used during hospital course. *denotes the current antimicrobial treatment to date. - denotes susceptibility data not provided.

P. aeruginosa susceptibility	Day 14	Day 18
Amikacin	Susceptible	Resistant
Aztreonam	Resistant	Resistant
Cefepime	Resistant	Resistant
Ceftazidime	Resistant	Resistant
Ceftazidime/avibactam	-	Susceptible
Ceftolozone/tazobactam	-	Susceptible
Ciprofloxacin	Susceptible*	Resistant*
Colistin	-	Susceptible
Gentamicin	Susceptible	Susceptible
Meropenem	-	Resistant
Minocycline	-	Resistant
Piperacillin/tazobactam	Resistant	Resistant
Tigecycline	-	Resistant
Tobramycin	Resistant	Susceptible*

On day 9, given persistently elevated WBC of 49.5 k/mm³, the patient was transitioned to an empiric antibiotic course of meropenem and vancomycin (Table 1). His hepatic function and hyperammonemia improved over the subsequent days, with serum ammonia on days 9-12 of 131 mmol/L, 97 mmol/L, 75 mmol/L, and 71 mmol/L respectively (Figure 1). Bronchial washings were obtained on day 12 for worsening secretions. On day 13, the patient's serum ammonia abruptly increased to 154 mmol/L (Figure 1), and a bronchial washing culture Polymerase Chain Reaction (PCR) identified *P. aeruginosa* pneumonia. At this time, his antibiotic treatment regimen was changed from meropenem and vancomycin to ciprofloxacin and vancomycin for suspected acquired resistance to meropenem. On day 14, following the antibiotic change, the patient's serum ammonia declined to 56 mmol/L (Figure 1), and culture sensitivity testing confirmed resistance to piperacillin/tazobactam and meropenem (Table 1). On day 16, inhaled tobramycin was added to the ciprofloxacin and vancomycin regimen due to worsening clinical status, leukocytosis, an increase in serum ammonia concentration to 71 mmol/L (Figure 1). On day 18, another tracheal aspirate sample confirmed *P. aeruginosa* with resistance to ciprofloxacin, meropenem, and piperacillin/tazobactam (Table 1). On day 19, the patient had improvement in clinical status, improving leukocytosis, and a decline in serum ammonia to 38 mmol/L (Figure 1). Unfortunately, the patient suffered subsequent unrelated complications, and ultimately succumbed to multi-organ failure on day 36.

Discussion

It is generally accepted that the degree of hyperammonemia does not correlate well with the clinical grade of hepatic encephalopathy, and for this reason, serum ammonia levels are not routinely trended. However, in patients with NHHA associated with sepsis, increased serum ammonia has been shown to be more reliably associated with microbial culture-proven sepsis than other classically associated markers of sepsis such as lactic acidosis. Nonhepatic hyperammonemia in sepsis is associated with significantly increased mortality, and hyperammonemia may be a marker of more severe or inadequately treated bacterial infection [2,6].

Additionally, hyperammonemia is associated with increased risk of sepsis-associated encephalopathy, which is independent-

ly associated with increased mortality, and which further underscores the importance of identifying and treating all sources of ammonia elevation [6,7].

In this case, the patient's liver injury peaked on hospital days 7 and 8, and improved afterward. The serum ammonia trend, which decreased after the initial hepatic injury, later correlated closely with the resistance patterns of his multi-drug resistant *P. aeruginosa* infection. In this particular case, we identified the rising serum ammonia trend on multiple occasions and suspected its correlation to emerging antibiotic resistance patterns, prompting us to change the antibiotic treatment regimen and observe clinical improvement.

Conclusions

Although NHHA is more classically associated with *E. coli* urinary tract and intestinal infections, this case highlights that many other infections including *P. aeruginosa* pneumonia can be a cause of NHHA. To these authors' knowledge, this is the first known report in the literature of using serum ammonia concentration to gauge response to therapy and identify early *P. aeruginosa* treatment failure due to antibiotic resistance. As such, this case highlights the utility of serum ammonia as an additional treatment biomarker in cases of infection with known urease-producing organisms. In cases of culture positive sepsis from urease-producing bacteria, further studies should seek to appraise serum ammonia as an early biomarker of illness severity and treatment effect.

Author Statements

Conflict of Interest

The authors have no conflicts of interest to declare.

Ethical Statement

The authors are accountable for all aspects of the work in ensuring that questions related to the accuracy or integrity of any part of the work are appropriately investigated and resolved. All medical care and procedures performed were in accordance with the ethical standards of our institution, ethics review boards, and with the Helsinki Declaration (as revised in 2013). The authors were unable to obtain signed consent from the guardian of the deceased patient, however the article has been sufficiently anonymized to cause no harm to the patient or his or her family.

Author Contributions

Christopher Tainter and Thomas Pederson were both directly involved in the care of this patient and contributed equally to authorship of the manuscript.

References

1. Long MT, Coursin DB. Undifferentiated non-hepatic hyperammonemia in the ICU: Diagnosis and management. *J Crit Care.* 2022; 70: 154042.
2. Zhao L, Gao Y, Guo S, Lu X, Yu S, Ge Z, et al. Prognosis of Patients with Sepsis and Non-Hepatic Hyperammonemia: A Cohort Study. *Med Sci Monit Int Med J Exp Clin Res.* 2020; 26: e928573-1-e928573-16.
3. Numan Y, Jawaid Y, Hirzallah H, Kusmic D, Megri M, Aqtash O, et al. Ammonia vs. Lactic Acid in Predicting Positivity of Microbial Culture in Sepsis: The ALPS Pilot Study. *J Clin Med.* 2018; 7: 182.
4. Hassan AAI, Ibrahim W, Subahi A, Mohamed A. 'All that glitters is not gold': when hyperammonaemia is not from hepatic aetiology. *BMJ Case Rep.* 2017; 2017: bcr2017219441.
5. Vince A, Dawson AM, Park N, O'Grady F. Ammonia production by intestinal bacteria. *Gut.* 1973; 14: 171-7.
6. Zhao J, He Y, Xu P, Liu J, Ye S, Cao Y. Serum ammonia levels on admission for predicting sepsis patient mortality at D28 in the emergency department. *Medicine (Baltimore).* 2020; 99: e19477.
7. Feng Q, Ai YH, Gong H, Wu L, Ai ML, Deng SY, et al. Characterization of Sepsis and Sepsis-Associated Encephalopathy. *J Intensive Care Med.* 2019; 34: 938-45.