

## Clinical Image

# Pancreatic Mass Mimicking Neuroendocrine Tumor

Ahn AR<sup>1</sup>, Song JS<sup>2</sup>, Yang JD<sup>3</sup> and Moon WS<sup>1\*</sup>

<sup>1</sup>Departments of Pathology, Jeonbuk National University Medical School, Research Institute of Clinical Medicine of Jeonbuk National University, Biomedical Research Institute of Jeonbuk National University Hospital, and Research Institute for Endocrine Sciences, Jeonju, Jeonbuk Republic of Korea

<sup>2</sup>Department of Radiology, Jeonbuk National University Medical School, Research Institute of Clinical Medicine of Jeonbuk National University, Biomedical Research Institute of Jeonbuk National University Hospital, and Research Institute for Endocrine Sciences, Jeonju, Jeonbuk Republic of Korea

<sup>3</sup>Department of General Surgery, Jeonbuk National University Medical School, Research Institute of Clinical Medicine of Jeonbuk National University, Biomedical Research Institute of Jeonbuk National University Hospital, and Research Institute for Endocrine Sciences, Jeonju, Jeonbuk Republic of Korea

\*Corresponding author: Moon WS, Department of Pathology, Jeonbuk National University Medical School, Research Institute of Clinical Medicine of Jeonbuk National University, Biomedical Research Institute of Jeonbuk National University Hospital, and Research Institute for Endocrine Sciences, Jeonju, Jeonbuk Republic of Korea

**Received:** January 19, 2021; **Accepted:** January 25, 2021; **Published:** February 01, 2021

## Clinical Image

A 68-year-old man presented to our hospital for the evaluation of an incidentally detected pancreatic mass. Serum tumor marker levels were within normal limits. On delayed-phase computed tomography, a homogeneous enhancing 1.8 cm-sized hypervascular mass was detected in the pancreatic head (Figure 1). As the radiologic impression was that of a neuroendocrine tumor, the patient underwent pylorus-

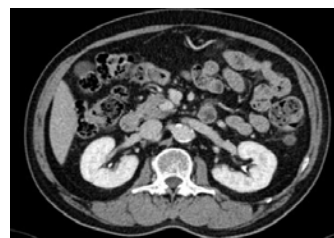

Figure 1: Hypervascular mass.

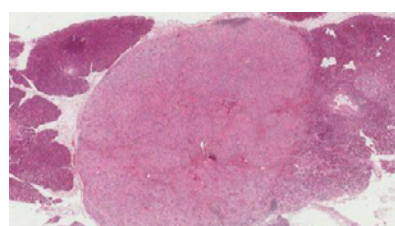


Figure 2: Pancreatic solid hamartoma.

preserving pancreatoduodenectomy. Microscopically, the tumor exhibited typical features of pancreatic solid hamartoma (Figure 2). Pancreatic solid hamartoma is an extremely rare entity that shows components that are present in the normal pancreas with distorted architecture and are considered as malformative lesions. Preoperative diagnosis is difficult because the clinicopathological features of solid hamartoma have not yet been fully clarified. The radiologic findings in this mass were similar to those of a neuroendocrine tumor. All patients with pancreatic hamartomas present with a benign clinical course. Recognition of this entity is desirable to avoid unnecessary extended surgical resection.