

## Clinical Image

## Blue Dot Cataract a Rare Case of Cataract

Hassina S<sup>\*</sup>; Krichene MA; Hasnaoui I; Bekkar B; Bardi S; Robbana L; Akkanour Y; Serghini L; Abdallah E; Berraho A

Department of Ophthalmology B, Specialty Hospital  
Rabat, Morocco

**\*Corresponding author:** Salma Hassina

Department of Ophthalmology B, Specialty Hospital  
Rabat, Morocco.

Email: drsalmahassina@gmail.com

**Received:** May 31, 2024

**Accepted:** June 24, 2024

**Published:** July 01, 2024

**Keywords:** Cataract; Blue dot

## Case Report

We report the case of a 23-year-old patient with Down's syndrome who presented for a change of glasses. On clinical examination, visual acuity was at 1-meter finger count for both eyes, 8/10 with correction of -12 on the right and -10 on the left. Ocular tone was normal. Examination of the anterior segment revealed cataracts in both eyes, with multiple small bluish spots scattered over the entire lens (Figure 1 & 2). The fundus showed a myopic staphyloma with diffuse chorioretinal atrophy. The patient underwent phacoemulsification cataract surgery, which was uncomplicated and easy to follow.

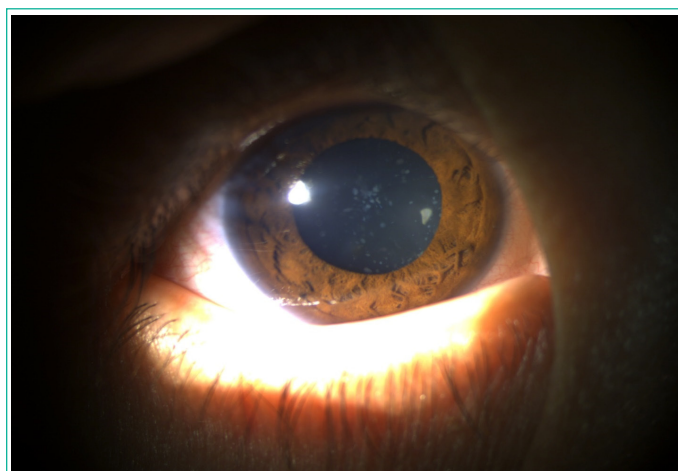


Figure 1: Blue dot cataract of right eye.



Figure 2: Blue dot cataract of left eye.