

Case Report

Fetal Congenital Heart Block

Velayo CL^{1*} and David IC²¹Department of Physiology, College of Medicine,
University of the Philippines, Philippines²Section of Maternal Fetal Medicine, Department of
Obstetrics and Gynecology, University of the Philippines -
Philippine General Hospital, Philippines*Corresponding author: Clarissa L Velayo,
Department of Physiology, College of Medicine,
University of the Philippines, 547 Pedro Gil Street corner
A. Mabini, Ermita, Manila 1000, PhilippinesReceived: September 13, 2021; Accepted: October 09,
2021; Published: October 16, 2021

Abstract

Objective: To report on the pathophysiology, diagnosis, and management of fetal congenital heart block.**Design:** Case series.**Setting:** University hospital.**Patients:** A 33-year old secundigravid with fetal congenital heart block secondary to structural heart disease; a 28-year old primigravid with isolated fetal congenital heart block secondary to maternal autoantibodies; and a 44-year old grand multipara with fetal congenital heart block, resolved.**Interventions:** Close fetal monitoring with cardiotocography, fetal wellbeing studies using ultrasonography with color Doppler velocimetry, and pacemaker insertion in the neonatal period.**Main Outcome Measures:** Cardiotocography and ultrasonography with Doppler revealed fetal congenital heart block. Further work-up involving autoantibody testing and fetal 2D-echocardiography revealed the underlying pathophysiology and classification of congenital heart block depending on the presence of structural heart anomalies or the existence of concomitant maternal disease.**Results:** The first two cases exemplified the different categories of congenital heart block: Case 1 illustrated heart block secondary to structural heart disease and Case 2 illustrated the isolated type secondary to maternal autoantibodies. Case 3 showed the typical clinical picture wherein no further progression but resolution of heart block symptoms occurred prenatally.**Conclusions:** This report emphasizes the importance of a high index of suspicion in the early diagnosis of fetal congenital heart block. Proper management for such cases entails close monitoring using available technology and not necessarily medical management in utero.**Keywords:** Congenital heart block; Arrhythmia; Congenital heart defects; Electrophysiology; Ultrasonography; Color doppler; Cardiotocography; Autoantibodies; Pacemaker

Introduction

Early cardiac electrophysiology is a dynamic process because the heart is constantly evolving in size, shape and function in utero and beyond the womb throughout the first year of life. Even more thought provoking is the added component of the underlying struggle between genetic structural predestination against forging environmental influences, as this case series shall illustrate. Congenital Heart Block (CHB) is the presence of conduction system disease of any form diagnosed on or before 28 days of life. Its reported incidence ranges from 1 in 15,000 to 1 in 20,000 livebirths [1-3]. Upon reviewing cases seen at our institution between 2010 to 2013, our local prevalence of CHB was similarly pegged at 1 in 21,053. When associated with structural heart disease, 1 in 2 CHB cases is diagnosed in utero with a poorer prognosis than the rest, which are diagnosed postnatally or in adulthood. For isolated CHB, those not associated with structural heart disease, the incidence ranges from 1 to 7.5 in 100 in all pregnancies positive for maternal autoantibodies [4]. Development of the cardiac conduction system occurs alongside the evolution of the primitive heart tube. As early as 5 weeks gestation,

rhythmic electrical depolarization of cardiac myocytes epitomize this nascent conduction system [5]. It is also at approximately 5 weeks of human development (Carnegie Stage 15) that evidence of nodal dominance and the ventricular conduction network have been recognized. Morquio described the first case of CHB as an "Impaired Atrioventricular Syndrome" in 1901, and characterized this condition as having a slow pulse, syncopal attacks and sudden death [6]. In 1966, Hull et al. recognized the association between CHB and maternal systemic lupus erythematosus (SLE) by reporting a case of a child born to a mother with active lupus [7]. In 1945, Plant and Steven reported the first case of fetal heart block [8]. Since then, various reports concerning CHB, its diagnosis and proposed therapies have been published leading to a better understanding of this rare disease although its primary etiology remains an enigma. Fetal arrhythmias, CHB included, are clinically detected by auscultation or routine obstetrical ultrasound. Fetal monitoring and fetal echocardiography with Doppler studies subsequently confirm these, and the latter is the gold standard for diagnosis as it determines the following: the level of block, the presence of major structural heart disease, the

Table 1: Summary of CHB cases.

Case	Gestational Age at CHB Diagnosis	Congenital Anomaly Scan findings	2D echocardiogram findings	Additional findings	Postnatal cardiac findings	Therapy
1	37 2/7 weeks	Complete heart block (3 rd Degree); Cardiomegaly (CTR=0.62); Minimal pericardial effusion; Cannot rule out septal defect	To consider CHB; Patent foramen ovale with right to left shunt; Minimal pericardial Effusion;	(-) ANA (-) SS A/Ro (-) SS B/La MCA PSV (normal)	ECG: CHB	For Pacemaker insertion
2	28 1/7 weeks	Complete heart block (3 rd Degree); Cardiomegaly (CTR=0.63)	Mild cardiomegaly with CTR of 0.62; atrial rate of 144-166 bpm; ventricular rate of 58-62 bpm; normal cardiac anatomy; foramen ovale, right to left; intact ventricular septum; normal RV and LV outflow tracts; normal aortic and ductal arches; good biventricular contractility; mild tricuspid regurgitation.	(+) ANA (+) SS A/Ro (+) SS B/La	ECG: CHB	Pacemaker inserted
3	29 6/7 weeks	NEGATIVE (at 22 weeks)	Consider congenital heart block; Irregular cardiac rhythm; Bradyarrhythmia (HR: 88-135); good biventricular contractility; no cardiomegaly.	(-) ANA (-) SS A/Ro (-) SS B/La	Normal cardiac findings; CHB resolved at 35 3/7 weeks AOG	None

presence of myocarditis, the presence of secondary changes of cardiac enlargement, the presence of tricuspid regurgitation, the presence of pericardial effusion, and the development of hydrops [9] Pivotal events in utero predetermine quality of life outside the confines of the womb. It is therefore imperative that clinicians properly diagnose and manage these cases of CHB although rare in practice.

Case Presentation

A summary of data from all three patients is shown in Table 1. Each case report is described below and accompanied by supporting figures.

Case 1

M.A., 33 years old, G2P1 (1001); Fetal congenital heart block (3rd degree); Cardiomegaly with minimal pericardial effusion; To consider septal defect This is the case of M.A. a 33 year old secundigravid referred to our institution for further management of congenital heart block. Both her past medical and family medical histories were unremarkable. Her first pregnancy resulted in a full term livebirth by spontaneous vaginal delivery. She had 3 pre-natal checkups at a local lying-in clinic. 6 days prior to admission, at 36 weeks and 3 days age of gestation (AOG), an irregularly irregular fetal heart rate and a possible septal defect was found on routine obstetrical ultrasound. She was immediately referred to our institution. On the day of admission, she was referred to our Perinatology section where a Congenital Anomaly Scan (CAS) confirmed the presence of cardiomegaly (cardiothoracic ratio or CTR=0.62), minimal effusion and fetal complete heart block (Figures 1-3). Intrapartal Monitoring (IPM) showed a Category II trace for areas of bradycardia dipping to as low as 60 bpm, lasting 30-90 seconds. The patient was subsequently admitted for control of preterm labor and further work-up of the CHB. The patient remained at our intensive maternal unit (IMU) for a total of 11 hospital days. Here, the patient was co-managed by several services: Neonatology, Pediatric cardiology and Genetics. Daily non-stress tests showed irregular fetal heart rate recordings with baseline shifts from 140-145 to as low as 55-60 bpm. A fetal 2D-echocardiogram 3 days after admission presented the following results: To consider CHB; patent foramen ovale with right to left shunt; minimal pericardial effusion.

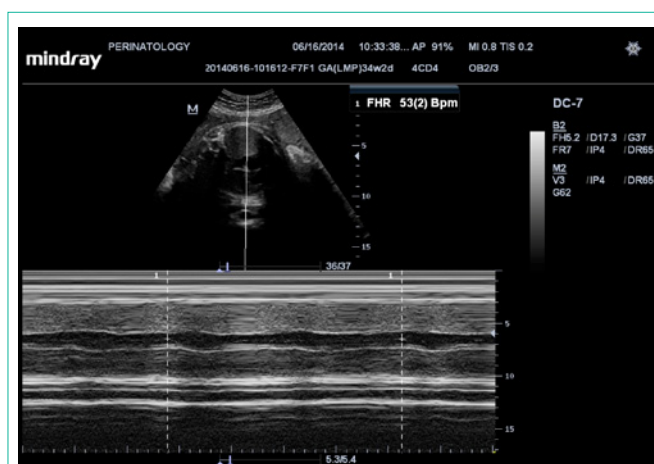


Figure 1: Fetal bradycardia of 53 bpm on congenital anomaly scan of Case 1.

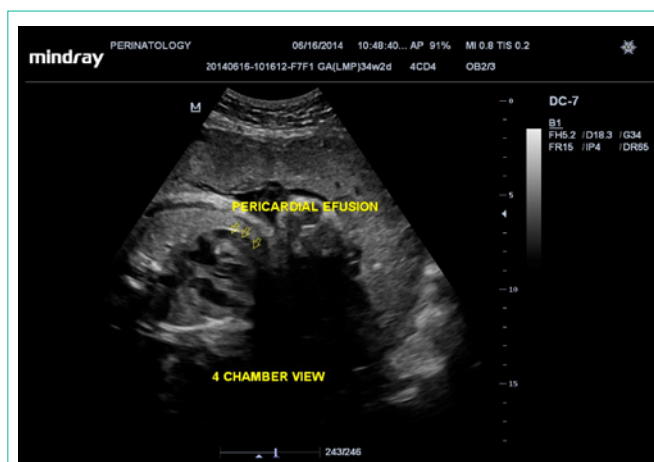


Figure 2: Minimal pericardial effusion on congenital anomaly scan of Case 1.

Testing for ANA, SSa/Ro and SSb/La were all negative. Middle cerebral artery velocities were within the normal range. An elective primary low segment Cesarean section was performed at 38 weeks

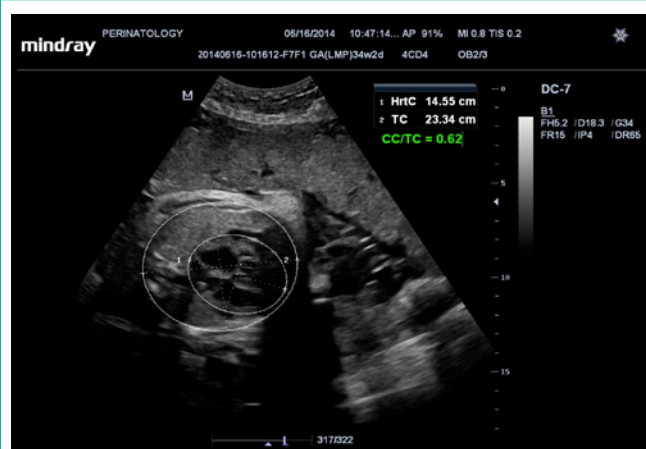


Figure 3: Fetal cardiomegaly (CTR = 0.62) on congenital anomaly scan of Case 1.

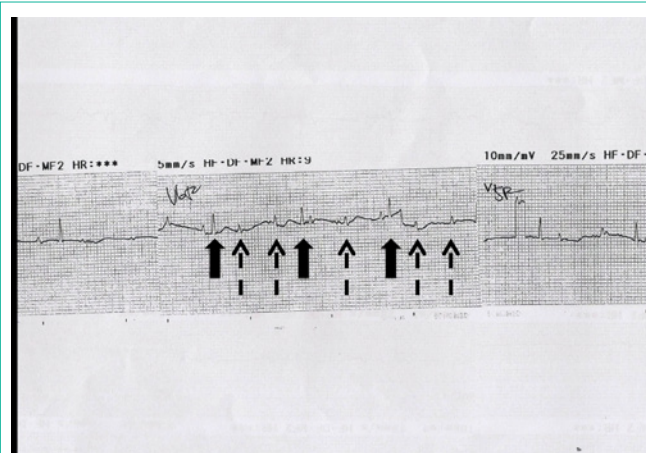


Figure 4: Electrocardiographic finding of complete heart block in the neonate of Case 1 (Solid arrows show ventricular depolarization while dashed line arrows show atrial depolarization).

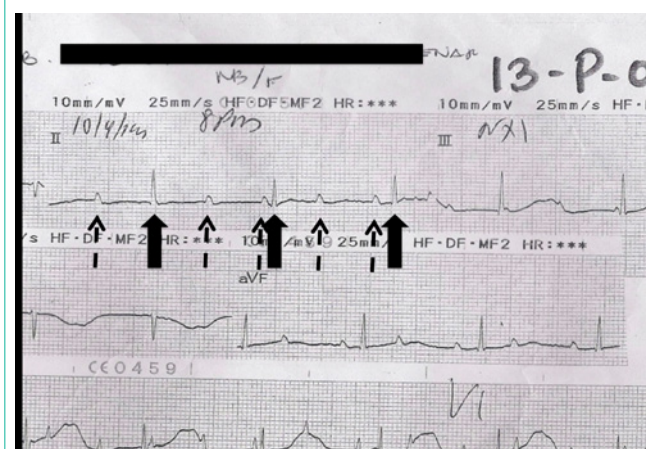


Figure 5: Electrocardiographic finding of complete heart block in the neonate of Case 2 prior to pacemaker insertion (Solid arrows show ventricular depolarization while dashed line arrows show atrial depolarization).

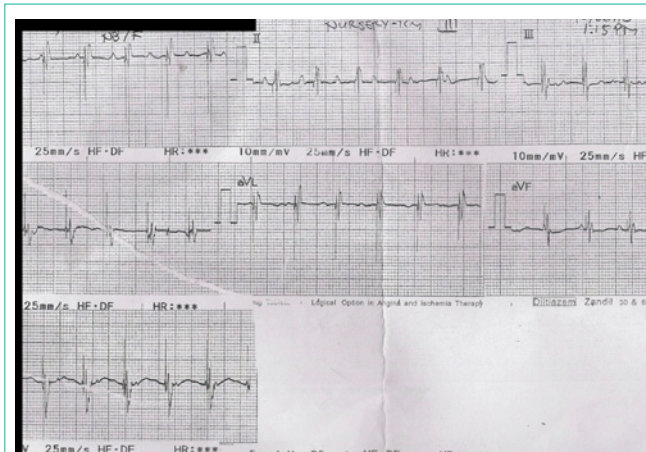


Figure 6: Electrocardiographic finding of resolution of complete heart block in the neonate of Case 2 after pacemaker insertion.

AOG and the patient delivered a full term live baby girl weighing 2420 grams, Appropriate for Gestational Age (AGA), 37 weeks by pediatric aging, APGAR 8, 8 (at 1 minute and 5 minutes respectively). The baby was admitted to the Neonatal Intensive Care Unit (NICU) for close monitoring and permanent pacemaker insertion (Figure 4).

Case 2

A.C., 28 years old, G1P0; Fetal congenital heart block (Isolated CHB, 3rd degree); Hashimoto's thyroiditis, clinically and biochemically euthyroid; Systemic lupus erythematosus, in evolution This is the case of A.E. a 28 year old primigravid previously diagnosed with Hashimoto's thyroiditis four years prior to consult and maintained on levothyroxine 100 mg daily. Family medical history was unremarkable. She had 6 pre-natal checkups at a private hospital. 6 days prior to consultation, bradycardia of 62 bpm was noted on routine ultrasound. The impression was single live intrauterine pregnancy compatible with 27 weeks and 5 days AOG by fetal biometry with bradycardia but with good somatic activity; female fetus in cephalic presentation, posterofundal placenta grade 0; adequate amniotic fluid volume; estimated fetal weight is appropriate

for gestational age; Biophysical Profile Score (BPS) is indicative of good fetal wellbeing. This prompted consult 3 days later to a tertiary center for fetal echocardiography with color Doppler. Their findings included: Mild cardiomegaly with CTR of 0.62; atrial rate of 144-166 bpm; ventricular rate of 58-62 bpm; normal cardiac anatomy; foramen ovale, right to left; intact ventricular septum; normal Right Ventricular (RV) and Left Ventricular (LV) outflow tracts; normal aortic and ductal arches; good biventricular contractility; mild tricuspid regurgitation. Testing conclusions were Complete Heart Block; no structural heart disease; no evidence of hydrops. She was advised further work-up but due to financial constraints, she opted to consult at our institution. On the day of consult, a full diagnostic work-up was performed and additional testing for SLE turned out positive for autoantibodies ANA, SSa/Ro and SSB/La. Thus, her complete working impression at our out-patient department by her 3rd follow-up was: Pregnancy uterine 34 4/7 weeks AOG by amenorrhea, cephalic not in labor; Fetal Congenital Heart Block (Isolated CHB, 3rd degree); Fetal cardiomegaly with minimal pericardial effusion; Hashimoto's thyroiditis, clinically and biochemically euthyroid; SLE in evolution. She was subsequently co-

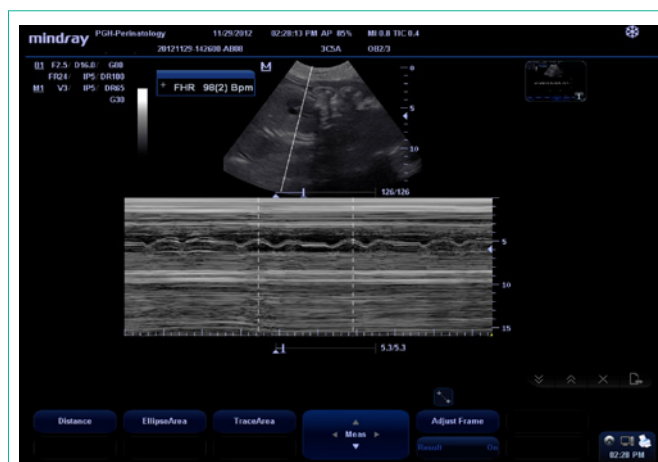

Figure 7: Bradycardia of 98 bpm noted on routine follow-up ultrasound scan of Case 3.

managed by several services: Pediatric Cardiology, Endocrinology, Rheumatology, Genetics and Neonatology. On the day of admission, the patient consulted at our Perinatology Section for routine ultrasound at 37 weeks and 3 days AOG. IPM showed a Category III trace for persistent late decelerations. An emergency primary low segment Cesarean section was performed for non-reassuring fetal status and the patient delivered a full term live baby girl weighing 2000 grams, small for gestational age (SGA), 38 weeks by pediatric aging, APGAR 8, 8 (at 1 minute and 5 minutes respectively). The baby was admitted to the NICU for close monitoring. Two days after birth, a temporary pacemaker was inserted followed by insertion of a permanent pacemaker six days later (Figures 5 and 6). The baby and mother were both discharged from the hospital in stable condition 14 days after delivery.

Case 3

G.R., 44 years old, G9P7 (7017); Fetal congenital heart block, resolved; Status post exploratory laparotomy, right nephrectomy for pyoureteronephrosis and right urolithotomy This is the case of G.R a 44 year old grand multipara known to our Perinatology service since 22 weeks AOG as she was co-managed with Urology for removal

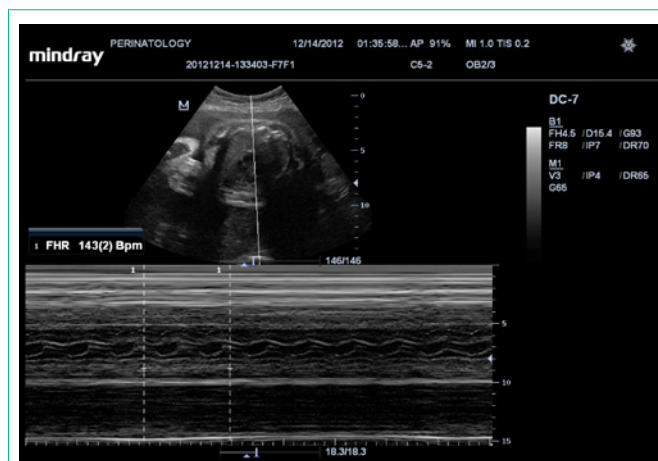


Figure 8: Resolution of congenital heart block at 35 weeks and 3 days in Case 3.

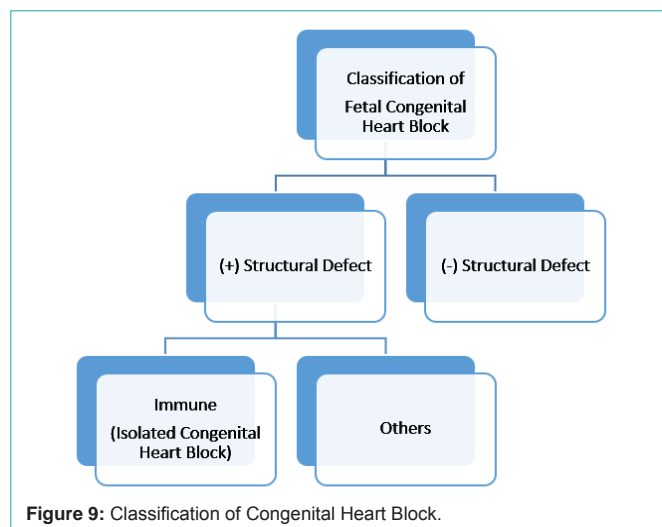


Figure 9: Classification of Congenital Heart Block.

of a renal mass during her first admission for this pregnancy. CAS done at 22 weeks was confirmed negative. Family medical history was unremarkable. She had a total of 8 pre-natal follow-ups at our high risk clinic. On the day of readmission (29 weeks and 6 days AOG), the patient was noted to have a decreasing fetal heart rate, which was as low as 50 bpm, during routine fetal wellbeing assessment. She was admitted for further management. Fetal 2D-echocardiogram results were as follows: Consider congenital heart block; Irregular cardiac rhythm; Bradyarrhythmia (HR: 88-135); good biventricular contractility; no cardiomegaly (Figure 7). Testing for ANA autoantibodies was negative. Both mother and fetus were subsequently discharged as no further intervention was necessary. She was advised close follow-up and frequent fetal wellbeing studies. At 35 weeks and 3 days AOG, the fetal congenital heart block was deemed to be resolved as close fetal monitoring through cardiotocography and ultrasound leading to this time showed no further evidence of CHB (Figure 8). This remained the case up until 39 weeks and 2 days when the patient delivered a full term live baby girl by spontaneous vaginal delivery, 40 weeks by pediatric aging, AGA, APGAR 9, 9 (at 1 minute and 5 minutes respectively). The baby was evaluated at the NICU and CHB was ruled out. Both mother and child were discharged in stable condition 4 days post-partum.

Discussion

Fetal congenital heart block is associated with pronounced morbidity and mortality such that a high index of suspicion is necessary to diagnose this condition early in gestation. The prognosis of these fetuses will depend on the following factors: first, the presence or absence of structural heart disease; second; the rate of ventricular activation (the critical value being less than 55 bpm); and third, the presence or absence of physiologic disturbances in cardiac function (such as congestive heart failure or the presence of hydrops fetalis) which is associated with the poorest prognosis [1]. Mortality rates reported depending on the developmental period of first appearance of CHB symptoms are 43% in fetuses, 6% in neonates and 0% in children, thus, the later CHB develops, the better is the chance of survival. On the other hand, based on symptoms, fetuses with hydrops fetalis or endocardial fibroelastosis incur a 100% rate of mortality [10]. Therefore, accurate prenatal diagnosis cannot be overemphasized

in such circumstances where it is a matter of definitive rather than palliative treatment after birth. The crux of electrocardiography is the intimate relationship between the cardiac nerve conduction system and the structural morphology of the heart [11]. This theme is vividly captured in the classification of CHB. Congenital heart block is categorized into two types depending on the presence of structural heart disease (Figure 9). CHB with congenital heart disease confers a 14% chance of survival in the neonatal period. The most common structural anomalies involved include left atrial isomerism and discordant atrioventricular connections. On the other hand, CHB without structural heart disease, also referred to as isolated CHB, confers an 85% chance of survival in the neonatal period. This second category is further subdivided into those associated with maternal autoantibodies or those associated with other diseases such as the storage disorders (Hurler's Syndrome and Hunter's Syndrome) [12]. Our first case illustrated CHB with structural heart disease. CHB develops directly as there is disruption of the conduction network from the onset. On Fetal Electrocardiography (fECG), severity of CHB would range from a first degree block in the form of a simple PR prolongation to a second degree block in the forms of Mobitz Type I (Wenkebach) or Mobitz Type II phenomena, or as seen in our patient, to a third degree block which is defined as either of the following: (a) regular RR intervals at a >1000 ms cycle length; or (b) regular PP intervals at <1000 ms cycle length; or (c) irregular PR intervals [13]. In our patient, a septal defect was suspected at the onset with symptoms of pericardial effusion, and although 2D-echocardiography did not confirm a structural anomaly, this could not be totally ruled out. Our second case illustrated CHB without structural heart disease and was secondary to maternal autoantibodies, otherwise known as isolated CHB. The peak onset of this type of CHB is at 18-24 weeks of gestation since maternal autoantibodies only begin to pass through the placenta at 12 weeks and symptoms will usually manifest only after 6 weeks of fetal exposure. The autoantibodies linked to CHB include increased levels of the antinuclear antibodies Sjogren Syndrome A (SSa) or Sjogren Syndrome B (SSb), both also known as Ro and La antibodies respectively after the initials of the patients from whom these were first detected. In this scenario, the hypothesized pathogenesis of CHB is due to the direct effect of these autoantibodies on calcium regulation in the fetal heart leading to cross reactive disturbances in signal conduction or electrogenesis or both [14-16]. Another hypothesis postulates that inflammatory immune reactions caused by the transfer of maternal autoantibodies initiate scarring and fibrosis via apoptosis in myocytes of the fetal heart eventually leading to disruption of the conduction system [17]. Our second case is a typical example of neonatal lupus, which is the passive acquisition of maternal autoantibodies in the fetus. As in the case of our index patient, half of mothers at diagnosis are usually asymptomatic for autoimmune disease and may only become aware of their illness because of this fetal manifestation. CHB in neonatal lupus will be at least of the second degree to third degree types. Moreover, only 1-7.5% of fetuses with neonatal lupus will develop CHB while the rest may have skin rashes (annular lesions mostly on the face around the eyes), liver abnormalities (elevated liver enzymes and jaundice), blood dyscrasias (such as cytopenias) and photosensitivity. These non-cardiac manifestations are transient and will subside once maternal autoantibodies are cleared beginning at the 8th month of life. Unfortunately, for those who develop conduction system disease,

this manifestation is irreversible. For mothers known to carry these autoantibodies and with a previously affected child, there is a 15-18% recurrence rate of neonatal lupus in subsequent pregnancies [17,18]. Finally, our third case exemplifies the common clinical scenario of transient in utero CHB. At this stage of development, both genetic and environmental insults may still undergo remodeling and repair due to the plasticity of the fetal heart. This immense ability to re-engineer itself remains a mystery as much as the true underlying etiology of congenital heart block still remains unknown leading researchers struggling with questions such as "is heart block a normal phenomenon in development towards structural normalcy?" Among the possible causes of transient in utero CHB are genetic ion channelopathies involving sodium and potassium ion channel unit defects. Whether transient or irreparable, these channelopathies have been linked to fetal intrauterine demise and sudden infant deaths. Current studies aim to identify genetic loci that carry these mutations [19]. The significance of reporting cases of CHB, although incidentally rare and most probably underreported, lies in the need for promoting awareness of the signs and symptoms of the disease. For CHB, universal screening is not advocated but a high index of suspicion should lead to proper diagnosis using ultrasound as the gold standard followed by fECG, MRI, autoantibody testing and genome arrays as confirmatory tests. Ongoing studies concerning perinatal management persist amidst their limited usefulness. The most recognized therapeutic approach is the use of transplacental treatments such as beta stimulants and steroids. The former includes ritodrine, terbutaline and salbutamol, all of which may effectively increase fetal ventricular rate by 10-20% and reverse hydrops, but their effects are short lived due to their brief duration of action [18]. On the other hand, the use of steroids, namely dexamethasone and betamethasone, is the most widely studied mode of therapy, especially in cases of CHB secondary to maternal autoantibodies. Steroids are known to directly effect treatment of AV block. Prompt administration of steroids after AV block onset may even improve the degree of AV block. Another target of steroid action is the prevention of myocarditis, which leads to fibrosis of the fetal heart. Steroid therapy though is not without its disadvantages. Chronic use may lead to increased infection, loss of bone density, diabetes, hypertension and cataracts in the mother, while fetal effects include oligohydramnios, adrenal suppression, intrauterine growth restriction and risk to the developing fetal brain. Furthermore, in various studies, the most famous of which being the PRIDE study (PR Interval and Dexamethasone Evaluation), results showed that there were no differences in mortality, prematurity, degree of final heart block or need for pacemakers in fetuses treated with steroids, but it was noted that the presence of pericardial or pleural effusions as well as ascites and hydrops seemed to improve with their use [4]. Other modes of therapy include Immunoglobulin (IVIG) administration and early delivery with direct pacing of the ventricle [2]. At present, therapeutic management in utero still remains controversial. First, CHB prophylaxis in SSa/Ro and SSb/La mothers is deemed impractical because only 1-7.5% of fetuses will develop CHB. Second, due to the low incidence of the disease, there is no singularly accepted standard protocol and third, most cases of CHB either transiently resolve or are detected at such advanced stages leaving no room for therapeutic benefits [20]. Carpenter et al. attempted the first fetal ventricular pacing in utero for hydrops secondary to complete atrioventricular block in 1986 [21].

Despite fetal death four hours after placement, the investigators concluded that such a procedure would lead to better chances of fetal survival if placed earlier in the course of fetal hydrops. Further attempts and research along this line of therapy have focused on sheep experiments [22]. Surviving cases of CHB will eventually require pacemaker insertion. The risk factors for requirement of a pacemaker are as follows: (1) mean resting heart rate below a determined number per age group (55 bpm in newborns); (2) symptomatic bradycardia (sudden presentation or limited exercise capability); (3) presence of significant structural heart disease; (4) significant pauses on 24-hr ambulatory electrocardiographic monitoring; and (5) a prolonged QTc interval or a wide QRS escape rhythm with complex ventricular ectopy [1]. Prognosis after pacemaker insertion is very good, therefore specialist care once diagnosed with CHB is imperative. In summary, three cases illustrating the different presenting scenarios of fetal CHB were reported and clearly, it is of utmost importance that understanding electrocardiac physiology is vital to the clinician whether in fetal, pediatric or adult medicine. In cases of fetal CHB, prompt diagnosis is key to direct a complete evaluation of both maternal and fetal conditions. Although sometimes vigilance alone and no intervention is required, continued investigation of the exact etiology and mechanism of development from all levels, molecular to anatomical, will lead to the discovery of a more effective mode of management.

References

- Friedman DM, Ducanson LJ, Glickstein J, et al. A review of congenital heart block. *Images Paediatr Cardiol*. 2003; 5: 36-48.
- Gandhi A, Patni S. Improving diagnosis of neonatal cardiovascular malformations: a genuine prospect or wishful thinking? *Arch Dis Child*. 2008; 93: 545-546.
- Sharland G. Fetal Cardiology. *Semin Neonatol*. 2001; 6: 3-15
- Buyon JP, Clancy RM, Friedman DM. Autoimmune associated congenital heart block: integration of clinical and research clues in the management of the maternal/foetal dyad at risk. *J Intern Med*. 2009; 265: 653-662.
- Moorman AF, de Jong F, Denyn MM, et al. Development of the cardiac conduction system. *Circ Res*. 1998; 82: 629-644.
- Machado MV, Tynan MJ, Curry PV, et al. Fetal complete heart block. *Br Heart J*. 1988; 60: 512-515.
- Hull D, Binns BA, Joyce D. Congenital heart block and widespread fibrosis due to maternal lupus erythematosus. *Arch Dis Child*. 1966; 41: 688-690.
- Plant RK, Steven RA, Maeno Y, Hirose A, Kanbe T, et al. Fetal arrhythmia: prenatal diagnosis and perinatal management. *J Obstet Gynaecol Res*. 2009; 35: 623-629.
- Lopes LM, Tavares GM, Damiano AP, et al. Perinatal outcome of fetal atrioventricular block: one-hundred-sixteen cases from a single institution. *Circulation*. 2008; 118: 1268-1275.
- Velayo CL, Sato N, Ito T, et al. Understanding congenital heart defects through abdominal fetal electrocardiography: case reports and clinical implications. *J Obstet Gynaecol Res*. 2011; 37: 428-435.
- Barnes N, Archer N. Understanding congenital heart disease. *Curr Paed*. 2005; 15: 421-428.
- Barateau AE, Fouchard S, Behaghel A, et al. Characteristics and long-term outcome of non-immune isolated atrioventricular block diagnosed in utero or early childhood: a multicentre study. *Eur Heart J*. 2012; 33: 622-629.
- Acherman RJ, Friedman DM, Buyon JP, et al. Doppler fetal mechanical PR interval prolongation with positive maternal anti-RNP but negative SSA/Ro and SSB/La auto-antibodies. *Prenat Diagn*. 2010; 30: 797-799.
- Karnabi E, Boutjdir M. Role of calcium channels in congenital heart block. *Scand J Immunol*. 2010; 72: 226-234.
- Cozzani E, Agnoletti AF, Pappalardo F, et al. The high incidence of anti-Ro/SSA and anti-p200 antibodies in female patients with connective diseases confirms the importance of screening for congenital heart block-associated autoantibodies during pregnancy. *Arch Dermatol Res*. 2016; 308: 139-143.
- Capone C, Buyon JP, Friedman DM, et al. Cardiac manifestations of neonatal lupus: a review of autoantibody associated congenital heart block and its impact in an adult population. *Cardiol Rev*. 2012; 20: 72-76.
- Ambrosi A, Wahren-Herlenius M. Congenital heart block: evidence of a pathogenic role of maternal autoantibodies. *Arthritis Res Ther*. 2012; 14: 208-218.
- Strasburger JF, Wakai RT. Fetal cardiac arrhythmia detection and in utero therapy. *Nat Rev Cardiol*. 2010; 7: 277-290.
- Brucato A, Grava C, Bortolati M, et al. Congenital heart block not associated with anti-Ro/La antibodies: comparison with anti-Ro/La-positive cases. *J Rheumatol*. 2009; 36: 1744-1748.
- Carpenter RJ Jr, Strasburger JF, Garson A Jr, et al. Fetal ventricular pacing for hydrops secondary to complete atrioventricular block. *J Am Coll Cardiol*. 1986; 8: 1434-1436.
- Boudjemline Y, Rosenblatt J, de La Villeon G, et al. Development of a new lead for in utero pacing. *Prenat Diagn*. 2010; 30: 122-126.