

Case Report

Superior Vena Cava Syndrome: Pathobiologic Mechanisms of Uremia on Vascular Wall Integrity?

Ghosheh Y¹, Phillips JS², Ahmed SH¹, Chilton RJ^{1*} and Jourdan Le Saux C¹

¹Division of Cardiology, University of Texas Health Science Center at San Antonio, USA

²Department of Medicine, University of Texas Health Science Center San Antonio, USA

*Corresponding author: Chilton RJ, Department of Cardiology, 27971 Smithson valley, University of Texas Health Science Center at San Antonio, 78261, USA

Received: November 06, 2014; Accepted: December 24, 2014; Published: December 28, 2014

Abstract

Superior Vena Cava (SVC) syndrome is caused from obstruction of blood flow through the SVC, which is frequently encountered in patients with malignancy. The incidence is believed to be increased by prior chemotherapy or radiation damage to the vessel wall. We critically examine a case of a 37-year old man who had end-stage renal disease and suffered an SVC rupture leading to pericardial tamponade. The potential pathobiologic mechanisms that could have contributed to the pericardial tamponade are discussed. Vascular pathobiologic effects from uremia should be considered in patients presenting with SVC and undergoing angioplasty.

Keywords: Pericardial tamponade; Extracellular matrix stability; Stent placement; Uremia

Abbreviations

SVC: Superior Vena Cava; CT: Computed Tomography; AGE: Advanced Glycation End Products; ECM: Extracellular Matrix; TG: Transglutaminase; TG2: Tissue Transglutaminase; TGF-β: Transforming Growth Factor-β; TGF-β1: Transforming Growth Factor-β1; CKD: Chronic Kidney Disease

Introduction

The clinical presentation of Superior Vena Cava (SVC) syndrome includes face, neck, and upper extremity swelling as well as dyspnea and cough (Figure 1) [1]. Up to 97% of patients presenting with SVC syndrome have malignant etiologies and the clinical presentations are then dramatically different from the patients without malignancies (Figure 2) [1,2]. Many will require treatment with either chemotherapy or radiation. The severity and development of symptoms has been correlated with the blood flow velocity and the degree of venous narrowing. Mechanically related vascular insults can contribute to SVC rupture during attempted stenting of venous obstruction that may in part be enhanced due to abnormal vascular wall integrity [3]. Other causes of vessel damage include elevated balloon dilation pressures, penetration of wire stent struts through the vessel wall [4], tumor involvement into the SVC [5], and repetitive dilation of the vessels [6]. Patients presenting with a history of Chronic Kidney Disease (CKD) may represent a different pathobiologic mechanism possibly due to uremic weakening of the vascular wall matrix [7,8]. These patients are well known to have a higher incidence of vascular disease than the general population [9]. We present an illustrative case of SVC rupture during balloon angioplasty in a male patient with end stage renal disease on hemodialysis.

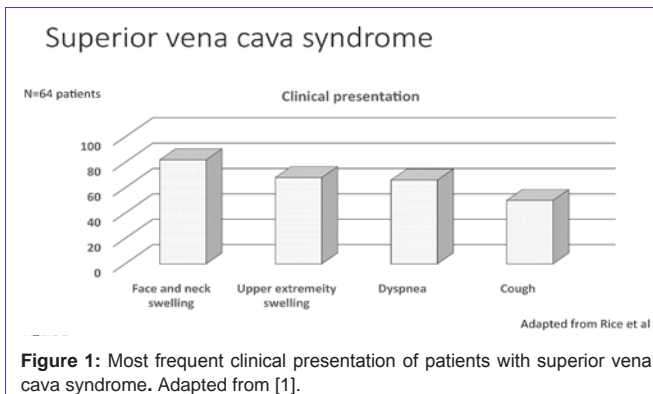
Case Report

A 37-year-old man presented with symptoms of facial swelling, tightness throughout the neck, and acute onset of dyspnea. His past medical history was significant for type two diabetes mellitus, hypertension and end stage renal disease on long-term hemodialysis. He previously had an arterio-venous fistula infection requiring the

placement of a right internal jugular venous perma-cath dialysis catheter that subsequently stenosed due to thrombosis. A left internal jugular venous perma-catheter was then placed for continuation of hemodialysis.

For five months he remained symptom free before again presenting with symptoms suggestive of SVC syndrome. On admission, he was hemodynamically stable and his exam was significant for grossly visible edema of the neck and face. A Computed-Tomography (CT) scan of the neck confirmed pre-vertebral swelling with subcutaneous edema within the anterior soft tissues. Venography revealed occlusion of the left brachiocephalic vein at the confluence of the left brachial and left internal jugular veins with multiple collateral venous channels flowing centrally towards the azygous system without opacification of the SVC (Figure 3A). Angioplasty of the brachiocephalic vein and SVC was performed with 10x40, 12x40 and 16x40 mm and 10x40, 12x40, 16x40 and 20x40 mm balloons respectively. Post-procedure venography demonstrated improved caliber of both vessels and a new 23cm cuff-to-tip perma-catheter was placed in the left internal jugular vein.

Immediately following replacement of the perma-catheter, the patient became profoundly hypotensive (systolic blood pressure 60 mmHg) and diaphoretic. Bedside echocardiography demonstrated



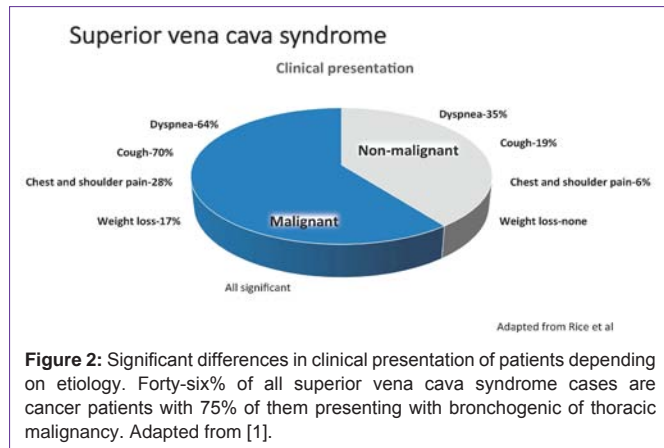


Figure 2: Significant differences in clinical presentation of patients depending on etiology. Forty-six% of all superior vena cava syndrome cases are cancer patients with 75% of them presenting with bronchogenic or thoracic malignancy. Adapted from [1].

a large pericardial effusion with signs of cardiac tamponade. Pericardiocentesis was urgently performed with approximately 300 cc of bloody fluid recovered. Despite these measures, the patient remained hemodynamically unstable and was emergently intubated. Repeat SVC venography revealed a focal perforation from the mid-upper SVC with active extravasation into the pericardial space (Figure 3B). Through the left common femoral vein, access was obtained using an 18Fr sheath. A 16x40 mm balloon was inflated for five minutes at the site of extravasation, but failed to achieve hemostasis. After consulting with cardiothoracic surgery, the perforation appeared amenable to seal using a covered stent. Using quantitative coronary arteriography, the SVC measured 22mm. A 26x33mm covered GORE EXCLUDER AAA Endoprosthesis (Gore Creative Technologies, Flagstaff, AZ) was deployed across the area of contrast extravasation. The stent was post-dilated with an 18x40mm balloon. Post-procedure venography demonstrated no further extravasation of contrast (Figure 3C). Flow of blood into the pericardial drain ceased and hemodynamics improved. A limited bedside echocardiogram and post-procedure CT scan of the chest both confirmed resolution of the effusion. The patient was admitted to the medical intensive care unit for monitoring. He was extubated on the second day and the pericardial drain was removed on the third day post-operatively. He had no further complications during his admission and was discharged home ten days later with no pericardial effusion on transthoracic echocardiography.

Discussion

The CKD population bears a higher burden of peripheral vascular disease than the population as a whole [9]. Studies have shown a convincing link between uremia and impaired cellular repair mechanisms, which may explain the increased prevalence of vascular disease in these patients [7-8,10-12]. Data from the 1970's and 80's were some of the first to elucidate the potential mechanisms at work [7,8,10]. One early study demonstrated that there was a direct correlation between rising uremia levels and a decline in collagen formation and wound tensile strength [8]. More recently, it has been shown that specific uremic solutes had the ability to inhibit endothelial cell proliferation and wound repair [12]. How uremia affects wound healing at the cellular level is unclear, but recent studies are beginning to shed light on the possible mechanisms at work.

Vascular dysfunction in patients with CKD, whether on dialysis or not, has been shown to involve endothelial dysfunction,

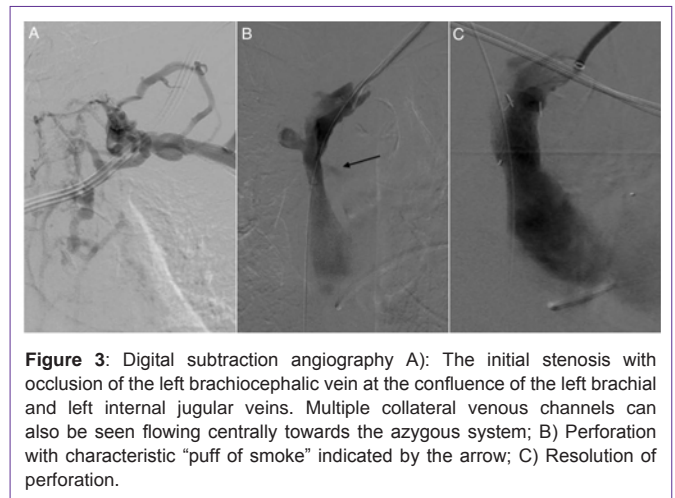


Figure 3: Digital subtraction angiography A): The initial stenosis with occlusion of the left brachiocephalic vein at the confluence of the left brachial and left internal jugular veins. Multiple collateral venous channels can also be seen flowing centrally towards the azygous system; B) Perforation with characteristic "puff of smoke" indicated by the arrow; C) Resolution of perforation.

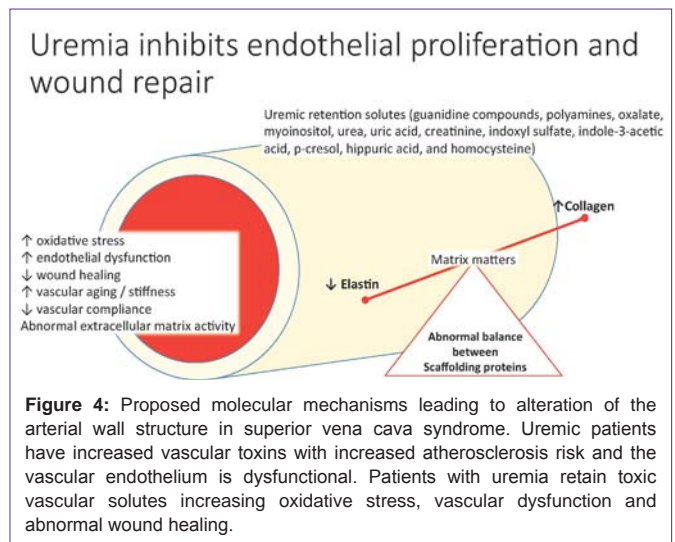


Figure 4: Proposed molecular mechanisms leading to alteration of the arterial wall structure in superior vena cava syndrome. Uremic patients have increased vascular toxins with increased atherosclerosis risk and the vascular endothelium is dysfunctional. Patients with uremia retain toxic vascular solutes increasing oxidative stress, vascular dysfunction and abnormal wound healing.

atherosclerosis, arterial stiffness, vascular calcifications, and intimal hyperplasia [13]. Loss of compliance of the vascular wall in uremic patients is linked to disequilibrium of its two prominent scaffolding proteins, collagen and elastin. Overproduction of abnormal collagen and diminished quantities of elastin, which is more susceptible to Advanced Glycation End Products (AGE) cross-linkings are evidenced (Figure 4) [14]. The nitric oxide pathway may also be inhibited directly by reactive oxygen species, AGE, and asymmetric dimethylarginine and indirectly by endothelial micro particles, possibly induced in uremia by the uremic toxins indoxyl sulfate and p-cresyl sulfate [15,16], leading to loss of compliance of the vascular wall [13].

Another important component of the vascular wall, which might be affected by uremic toxins, is the Extra Cellular Matrix (ECM). It provides a structural framework for elastin, collagen, proteoglycans, and structural glycoproteins and bears most of the wall tension generated by blood pressure. Under normal conditions, the ECM turnover is strictly controlled [17,18]. In vascular pathologies, the balance between proteases and their inhibitors is temporally altered through the induction of matrix metalloproteinase gene expression or the secretion of enzymes by inflammatory cells. Smooth muscle cells have an increased response to injury through their ability to

synthesize extracellular matrix molecules and protease inhibitors. However, the three dimensional organization of the newly synthesized extracellular matrix is never functionally optimal. In some cases the injury overcomes the responsive capacity of smooth muscle cells and the quantity of ECM decreases; consequently, the vascular wall integrity is compromised [18].

The role of the Transglutaminase (TG) family of enzymes in ECM remodeling was suggested by evidence of its presence at high levels in endothelial and vascular smooth muscle cells and by its role in angiogenesis during wound healing [19]. Mechanical forces, particularly blood flow-derived shear stress, are potent stimuli for arterial remodeling. Among several pathways, the stabilization of the ECM involves TGs through cross-linking of fibrinogen, fibronectin, type III collagen N-propeptide, and type VII collagen [20]. TG catalyzes a posttranslational modification of proteins, which leads to the formation of a protease stable isopeptide bond within or between polypeptide chains. A new γ -amide bond between a γ -carboxamide group of peptide-bound glutamine residues and a primary amine is formed by Ca^{2+} dependent acyl-transfer reaction [21]. Specifically, tissue Transglutaminase (TG2) contributes significantly to the organization of ECM by mediating cell-matrix interactions that affect cell spreading and migration and are crucial for wound healing [22]. The transamidase activity of TG2 plays a role in matrix stabilization and in the cross-linking of proteins during apoptosis. For example, it stabilizes the ternary formation of TG2: fibronectin: collagen complexes. It has an adapter function by facilitating cell adhesion to fibronectin through interacting directly with integrin's, or alternatively through heparin sulfate chains of the heparin sulfate proteoglycan receptor [23].

TG2 also has a role in the activation of Transforming Growth Factor- β (TGF- β) in the ECM [21]. TGF- β pathway is important in matrix regulation in health and disease, and is now recognized as a key component in the pathogenesis of thoracic aortic aneurysms [24]. TGF- β 1 leads to matrix degradation through increased production of plasminogen activators and release of matrix metalloproteinases 2 and 9 in the matrix [25]. Pathologic TGF- β 1 activity has been reported in several heritable connective tissue disorders associated with a high incidence of aneurysm and dissection formation such as in Marfan syndrome, Loays-Dietz syndrome, and Shprintzen-Goldberg syndrome [26].

TG2 has a pivotal role in inflammatory diseases, such as angiogenesis and wound healing [27]. It is an important effect or in the pathogenesis of chronic inflammatory diseases by converting the latent transforming growth factor binding protein-1 into its active form, TGF- β [28]. TG2 has been shown to be directly involved in CKD, where it is involved in the pathogenesis of vascular calcification through the enhancement of matrix vesicle-ECM interaction [29,30].

In summary, we propose elevated levels of uremia could weaken the vascular wall in CKD patients and increase their risk for rupture when intravascular therapies are performed.

References

- Rice TW, Rodriguez RM, Light RW. The superior vena cava syndrome: clinical characteristics and evolving etiology. *Medicine (Baltimore)*. 2006; 85: 37-42.
- Smith SL, Manhire AR, Clark DM. Delayed spontaneous superior vena cava perforation associated with a SVC wallstent. *Cardiovasc Intervent Radiol*. 2001; 24: 286-287.
- Mesurole B, Qanadli SD, Merad M, Mignon F, Baldeyrou P, Tardivon A, et al. Unusual radiologic findings in the thorax after radiation therapy. *Radiographics*. 2000; 20: 67-81.
- Chang SN, Chi NH, Lee WJ, Hsu KL, Chiang FT, Tseng CD. Cardiac Tamponade after Stenting for Superior Vena Cava Obstruction. *ActaCardiol Sin*. 2009; 25:161-164.
- Da Ines D, Chabrot P, Motreff P, Alfidja A, Cassagnes L, Filaire M, et al. Cardiac tamponade after malignant superior vena cava stenting: Two case reports and brief review of the literature. *Acta Radiol*. 2010; 51: 256-259.
- Oshima K, Takahashi T, Ishikawa S, Nagashima T, Hirai K, Morishita Y. Superior vena cava rupture caused during balloon dilation for treatment of SVC syndrome due to repetitive catheter ablation--a case report. *Angiology*. 2006; 57: 247-249.
- Colin JF, Elliot P, Ellis H. The effect of uraemia upon wound healing: an experimental study. *Br J Surg*. 1979; 66: 793-797.
- Kursh ED, Klein L, Schmitt J, Kayal S, Persky L. The effect of uremia on wound tensile strength and collagen formation. *J Surg Res*. 1977; 23: 37-42.
- Garimella PS, Hart PD, O'Hare A, DeLoach S, Herzog CA, Hirsch AT. Peripheral artery disease and CKD: a focus on peripheral artery disease as a critical component of CKD care. *Am J Kidney Dis*. 2012; 60: 641-654.
- Yue DK, McLennan S, Marsh M, Mai YW, Spaliviero J, Delbridge L, et al. Effects of experimental diabetes, uremia, and malnutrition on wound healing. *Diabetes*. 1987; 36: 295-299.
- Seth AK, De la Garza M, Fang RC, Hong SJ, Galiano RD. Excisional wound healing is delayed in a murine model of chronic kidney disease. *PLoS One*. 2013; 8: e59979.
- Dou L, Bertrand E, Cerini C, Faure V, Sampol J, Vanholder R, et al. The uremic solutes p-cresol and indoxyl sulfate inhibit endothelial proliferation and wound repair. *Kidney Int*. 2004; 65: 442-451.
- Brunet P, Gondouin B, Duval-Sabatier A, Dou L, Cerini C, Dignat-George F, et al. Does uremia cause vascular dysfunction? *Kidney Blood Press Res*. 2011; 34: 284-290.
- Konova E, Baydanoff S, Atanasova M, Velkova A. Age-related changes in the glycation of human aortic elastin. *Exp Gerontol*. 2004; 39: 249-254.
- Faure V, Dou L, Sabatier F, Cerini C, Sampol J, Berland Y, et al. Elevation of circulating endothelial microparticles in patients with chronic renal failure. *J Thromb Haemost*. 2006; 4: 566-573.
- Meijers BK, Van Kerckhoven S, Verbeke K, Dehaen W, Vanrenterghem Y, Hoylaerts MF, et al. The uremic retention solute p-cresyl sulfate and markers of endothelial damage. *Am J Kidney Dis*. 2009; 54: 891-901.
- Langille BL, Dajnowiec D. Cross-linking vasomotor tone and vascular remodeling: a novel function for tissue transglutaminase? *Circ Res*. 2005; 96: 9-11.
- Jacob MP. Extracellular matrix remodeling and matrix metalloproteinases in the vascular wall during aging and in pathological conditions. *Biomed Pharmacother*. 2003; 57: 195-202.
- Telci D, Griffin M. Tissue transglutaminase (TG2)--a wound response enzyme. *Front Biosci*. 2006; 11: 867-882.
- Miyazaki T, Ise M, Seo H, Niwa T. Indoxyl sulfate increases the gene expressions of TGF-beta 1, TIMP-1 and pro-alpha 1(I) collagen in uremic rat kidneys. *Kidney Int Suppl*. 1997; 62: S15-22.
- Lorand L, Graham RM. Transglutaminases: crosslinking enzymes with pleiotropic functions. *Nat Rev Mol Cell Biol*. 2003; 4: 140-156.
- Qian RQ, Glanville RW. Alignment of fibrillin molecules in elastic microfibrils is defined by transglutaminase-derived cross-links. *Biochemistry*. 1997; 36: 15841-15847.
- Iismaa SE, Mearns BM, Lorand L, Graham RM. Transglutaminases and

- disease: lessons from genetically engineered mouse models and inherited disorders. *Physiol Rev.* 2009; 89: 991-1023.
24. Wheeler JB, Ikonomidis JS, Jones JA. Connective tissue disorders and cardiovascular complications: the indomitable role of transforming growth factor-beta signaling. *Adv Exp Med Biol.* 2014; 802: 107-127.
25. El-Hamamsy I, Yacoub MH. Cellular and molecular mechanisms of thoracic aortic aneurysms. *Nat Rev Cardiol.* 2009; 6: 771-786.
26. Wu D, Shen YH, Russell L, Coselli JS, LeMaire SA. Molecular mechanisms of thoracic aortic dissection. *J Surg Res.* 2013; 184: 907-924.
27. Verderio EA1, Johnson TS, Griffin M. Transglutaminases in wound healing and inflammation. *Prog Exp Tumor Res.* 2005; 38: 89-114.
28. Nunes I, Gleizes P-E, Metz C, Rifkin D. Latent Transforming Growth Factor- β Binding Protein Domains Involved in Activation and Transglutaminase-dependent Cross-Linking of Latent Transforming Growth Factor- β . *The Journal of Cell Biology.* 1997; 136: 1151-1163.
29. Odii B, Coussons P. Biological Functionalities of Transglutaminase 2 and the Possibility of Its Compensation by Other Members of the Transglutaminase Family. *The Scientific World Journal.* 2014; 2014.
30. Chen NX, O'Neill K, Chen X, Kiattisunthorn K, Gattone VH, Moe SM. Transglutaminase 2 accelerates vascular calcification in chronic kidney disease. *Am J Nephrol.* 2013; 37: 191-198.