

## Editorial

# A Historical Dreaded Human Nematode Parasite, Dracunculus Worm (*Dracunculus medinensis*) Whose Awe is Still Alive in Elderly of India! Can't it Reappear in India?

**Choubisa SL\***Department of Advanced Science and Technology,  
National Institute of Medical Science and Research,  
NIMS University Rajasthan, India**\*Corresponding author:** Choubisa SL, Department  
of Advanced Science and Technology, National Institute  
of Medical Science and Research, NIMS University  
Rajasthan, Jaipur, Rajasthan 303121, India**Received:** September 27, 2022; **Accepted:** October 28,  
2022; **Published:** November 04, 2022**Abstract**

In the eighties, there was a tremendous infestation of dreaded human nematode parasite, Dracunculus worm (*Dracunculus medinensis*) in the rural areas of many states of India. Commonly, this roundworm is also known as Guinea worm. Thousands of people were suffering from Guinea worm disease (dracunculiasis), a disease caused by this viviparous female worm. In this water-borne disease, this worm is 1-3 feet long, milk-white, thin, cylindrical, and thread-like from any part (arms, legs, neck, breast, chest, abdomen, back, genital organs, etc.) of the person's body, slowly comes out over a period of 2-3 months. But this worm comes out more from those organs which come more in contact with water, because it makes it easier for it to complete its life cycle. During its emergence, the person feels very severe unbearable pain. Sometimes more than one worm has also been seen coming out of a person's body, which is an even more serious condition. India is now completely free from this dangerous worm and it was last seen in 2006. Now this is a historical human nematode roundworm whose description is only available in the pages of medical and parasitological history. But now these can be seen in the museum of zoology departments and medical colleges in the form of preserved specimens as evidence. But the old people of dracunculiasis endemic villages still tremble with fear after hearing its name. It is true that the history of this historical Dracunculus worm was very scary and dangerous. However, in India, the young generation is unfamiliar or unknown of this historical worm. There is no doubt that people have got freedom from this worm, but due to its eradication, another new health problem of chronic fluorosis has come in India, which is even more dangerous and painful than this. Due to this, not only thousands of people of all age groups, but many species of domestic animals became victims of lameness, that is, "fell from the sky and got stuck in the palm". There is no doubt that this worm has ended from India, but the question is also that can it not come back? Because many other beings are its reservoir hosts in which it is hidden. Whatever it is, its fate lies in the womb of the future.

**Keywords:** Cyclops; Definitive-host; Dracunculus worm (*Dracunculus medinensis*); Dracunculiasis; Endoparasite; Fluorosis; Guinea worm; Nematode (roundworm); Infection; Intermediate-host; India; Viviparous

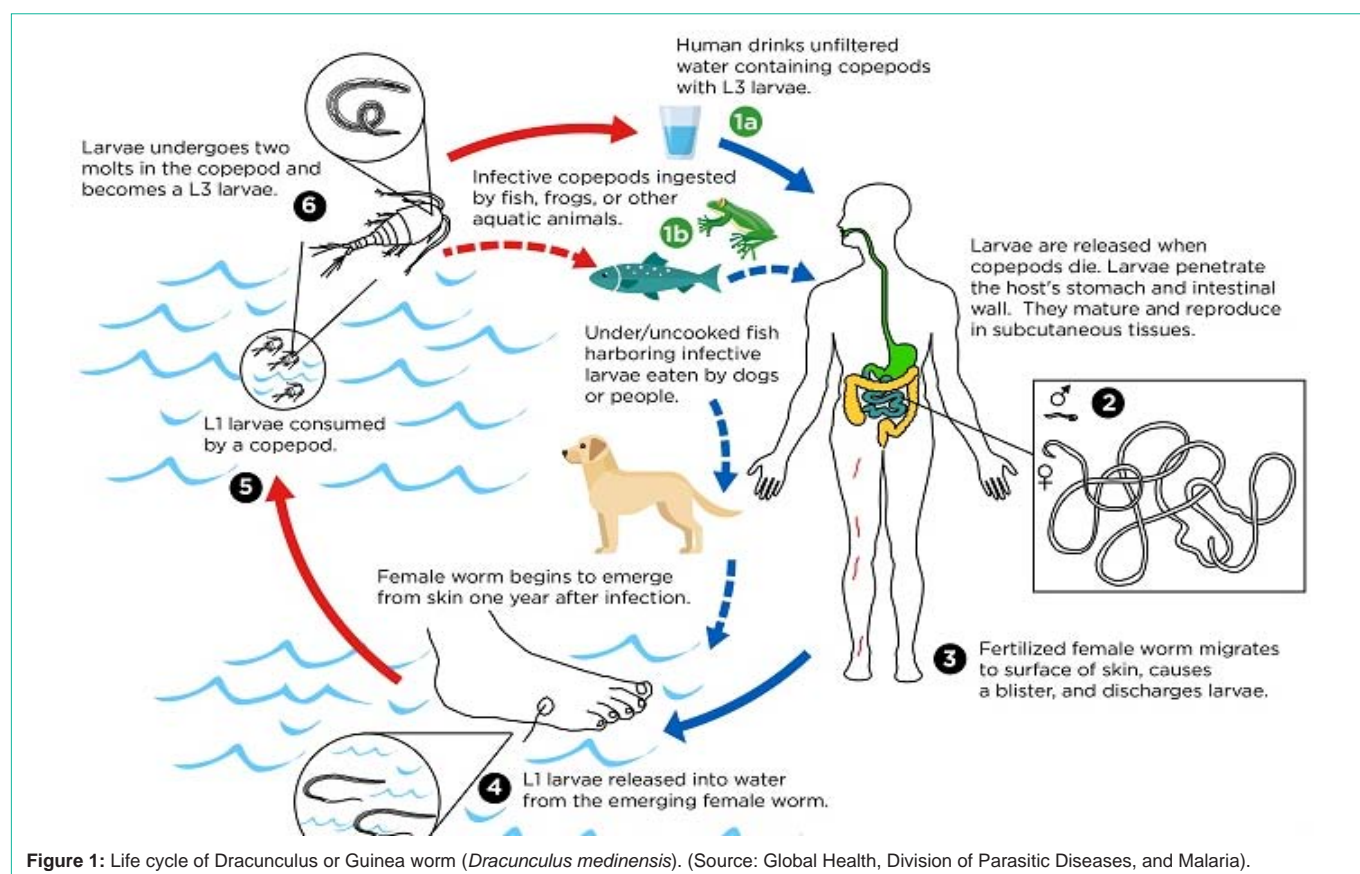
**Introduction**

In India, before the 1980, thousands of villages, helmets, and small towns in many states where the voices of pain filled with cries were heard from the women and men of every age before the starting of rainy season. Actually, these people were infected with the 50-150 cm long and 1.7 mm in width white or creamy nematode roundworm known as Dracunculus (*Dracunculus medinensis*) which caused them to suffer extremely unbearable pain. Commonly, this worm is also known as Guinea worm (Naru in India). This viviparous and endoparasite nematode roundworm is belonging to Phylum Nematoda, Class Phasmodia (Secernentea), Order Dracunculioidea, and Family Dracunculidae, which resides in the subcutaneous tissues below the human skin [1,2]. The disease caused by their infection

is called dracunculiasis or Guinea worm disease. This incurable disease only caused by the infection of the female Dracunculus worm. In general, the male worms are shorter than female worms having a short life span and they often die after the completion of copulation process [1,2]. The life cycle of Dracunculus is digenetic and completed in two different hosts, definitive or primary (man and other mammals) and intermediate (Cyclops, a copepod crustacean) host (Figure 1). In fact, Guinea worm disease in humans is spread by drinking water contaminated with these Cyclops infected with the embryos or larvae of this worm.

**Guinea Worm Endemic States and Its Fear**

Although the actual information about how this dreaded nematode roundworm came to India is not yet clear. But it was first



**Figure 1:** Life cycle of Dracunculus or Guinea worm (*Dracunculus medinensis*). (Source: Global Health, Division of Parasitic Diseases, and Malaria).

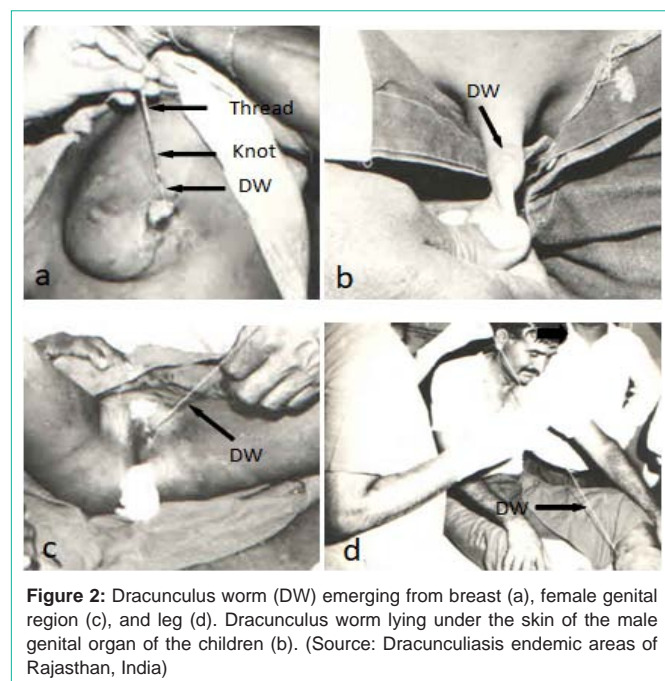
seen in the Medina of western Saudi Arabia. Probably from there it has reached other countries including India by infected people. Whatever be the case, the outbreak of this worm in India has been highest in the rural and remote areas of the states of Andhra Pradesh, Gujarat, Karnataka, Madhya Pradesh, Maharashtra, Rajasthan, Tamil Nadu, and Telangana [3-10]. But there was a tremendous outbreak especially in the rural tribal areas of Rajasthan state and almost all the tribal villages were endemic of dracunculiasis disease. In these areas, Guinea worm became the victim of every person who used to drink unfiltered water of perennial ponds, open wells, and stepwells (Bavadies). The people suffering from it were forced to suffer unbearable pain in their home or on the cot for 2-3 months. Its fear among the people was such that any person was afraid to go for a job in dracunculiasis endemic rural areas of these states. Sometimes the government would transfer such officers and employees to these dracunculiasis endemic areas on the basis of punishment, who used to be apathetic in government work. At that time, there was so much fear of this worm in the rural areas of the country that people used to get scared by its name. Its horror is still present in the memories of the elderly. But today's young generation is ignorant about this historical dangerous worm.

## Dracunculus Emergence and Its Life Cycle

This worm does not discriminate on the basis of sex and age and can infect any person who ingests water contaminated with Cyclops infected with *Dracunculus* embryos or larvae. Usually only one worm infection has been seen in a person but more than one has also been reported [11]. But such cases are rare in occurrence. Pregnant or

gravid female *Dracunculus* worm is completely moulded to adapt to its surrounding environment. Due to which it can easily move from one place to another in the whole body between the muscles and the skin. This worm can come out from any place of the body. It has also been seen to emerge from delicate organs like genital organs, breast, mouth, etc. (Figure 2a-c) which is more painful. But it comes out more from those organs which come in contact with water frequently, such as arms and feet (Figure 2d). Its special thing is that it comes out from the posterior end while its anterior end (mouth) remains in the human body. In fact, such adaptive behaviours help to complete the life cycle of this worm. Interesting, its uterus is prolonged from anterior to posterior end of the body and full of innumerable embryos or larvae, so that it can be successful in keeping its existence or lineage alive by infecting more and more people.

Female *Dracunculus* worm of often emerging or comes out of the body of people around the rainy season, which is a suitable time to complete its life cycle. Prior to its exit, the person is complaining of high fever, dizziness, vomiting, etc. The place from where this worm emerges becomes red and swollen (oedema). There are also sweet itching and with the intense irritation. Simultaneously, there is an appearance of a small coin shaped blister (Figure 3) with full of fluid. In the blister the tip (posterior end) of the female worm a white sprout from a microscopic wound in the middle. It takes about 2-3 months to complete the exit. If this breaks down for some reason during this period, then it starts re-entering and re-emerging from another place due to which the sufferer has to suffer more dangerous and very pains once more.

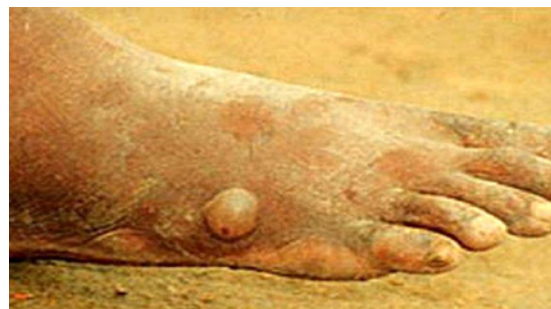

When a patient of dracunculiasis keeps the infected parts, such as hands and feet in cold water of a reservoir, he gets great relief from the burning sensation and feels very good. The female *Dracunculus* or Guinea worm takes advantage of this opportunity and releases its subtle coiled embryos (larvae) in water in thousands, which swallow micro crustacean fleas (*Cyclops*) present in water of diverse drinking water sources, such as ponds, bore wells, step-well etc. These embryos can survive for 5-7 days without eating anything in the water. When a person drinks without filtrated water from these drinking water sources, then these infected fleas also enter into the body. In this way, this worm cleverly completes its life cycle.

## Eradication Strategy and Its Consequences

To eliminate the problem of this worm from the country, the “Guinea Worm Eradication Project” was started in 1984. The main strategy of this project was to break the life cycle of this worm in any way. This strategy proved effective in its eradication. In order to avoid infected *Cyclops* in the body of people, people were made more and more educated for the awareness for drinking of filtrated water. Simultaneously, providing a water filter made of special cloth was given to each household in Guinea worm endemic villages. On the other hand, all the water sources (wells) of conventional drinking water were discontinued, while hand-pump and bore wells were dug in those areas where dracunculiasis is endemic to provide clean and non-contaminated water to the people. This way, the number of Guinea worm cases from year to year decreased.

In India, according to official figures, the dracunculiasis patient was last seen in the village of Jodhpur district of Rajasthan in 1996, but according to published research papers, it was finally seen in 2006 in the 40 year old Bhil tribal youth in the tribal belt of Dungarpur district of Rajasthan state. In 2000, the World Health Organization (WHO) has officially announced that now India is free from this malignant parasitic worm. It may be a very enthusiastic and quick



**Figure 3:** A blister (indicated by arrow) formation prior to emergence of *Dracunculus* worm. This is the one of the important diagnostic feature of dracunculiasis (Source: Google).

decision. However, it would probably be better if the decision was taken after repeated surveys in the tribal rural and remote dracunculiasis hyperendemic areas such as in the state of Rajasthan. Dracunculiasis or infection of *Dracunculus* worm, though it is now the pages of history, but its calcified residues remains still seen in some elderly X-ray films. Now students of medical and zoology rarely or cannot see the *Dracunculus* worm alive or in the living condition. They will now be able to read and learn about it only in their textbooks. If in their college museums have the preserved samples or specimen of worm then they can see it. At the same time, the elderly people must tell the story of the horror of this worm to their younger generation.

Whatever happens, the disease or *Dracunculus* worm has gone away from the country but in turn, there is a dangerous chronic fluorosis disease. In fact, during this eradication mission, hundreds of head-pumps and bore wells were dug in the villages to provide safe water to the people. But no one was aware of the amount of fluoride chemical in the water of these drinking water sources exceeding the prescribed norms [12,13]. It was discovered when people started drinking water from these sources and symptoms of chronic fluorosis started showing in them. Not only humans but their pets also started falling prey to this fluorosis disease [14,15]. In fact, this disease is the consequence of this highly successful project, due to which thousands of people and domesticated animals of rural areas in the country are becoming victims of lameness [16-32].

## Conclusion

The dracunculus or Guinea worm from India may have ended now but its terror is still present in the memory of the elders. However, young generation is ignorant about this worm. It is now a historical worm whose terror history will now be found only in zoological, parasitological, and medical text books. The ‘*Dracunculus* Worm Eradication Mission’ in India may have been successful, but it resulted in water-borne fluorosis disease among people as well as in their domestic animals [14,15], which is even more dangerous, i.e. “fell from the sky and got stuck in the palm”. There is no doubt that this worm has ended from India, but the question is also that can it not come back? Because many other beings are its reservoir hosts in which it is hidden. Whatever it is, its fate lies in the womb of the future.

## Acknowledgements

The author thanks to Dr. Anurag Choubisa, Geetanjali Medical

College and Hospital, Udaipur, Rajasthan 313002, India for cooperation.

## References

- Kotpal RL. Modern Textbook of Zoology Invertebrates. 8th Edition, Rastogi Publications, Meerut, India. 1999.
- Arora DR, Arora BB. Medical Parasitology. 3rd Edition, CBS Publishers and Distributors (Pvt.) Ltd., New Delhi, India. 2010.
- Baldhaiya GS, Marwaha SM, Patidar SR. An epidemiological assessment of dracontiasis. *Journal of Indian Medical Association*. 1969; 52: 67-71.
- Chopra RL. Magnitude of guinea worm infestation in Rajasthan with a survey of three districts. *Rajasthan Medical Journal*. 1967; 7: 225-227.
- Choubisa SL. Guinea worm (*Dracunculus medinensis*) in Rajasthan, India: A case report. *Journal of Parasitic Diseases*. 2002; 26: 105-106.
- Ismail Q, Dhakad NK, Pandey S. *Dracunculiasis* caused by polluted water in Dhar district of M.P. *Proceedings of Academic Environmental Biology*. 1997; 6: 83-86.
- Johnson J. *Dracontiasis: an overview. Perspectives in parasitology*. Printed House, Liuchow, India. 1985: 1.
- Choubisa SL, Verma R, Choubisa L. *Dracunculiasis* in tribal region of southern Rajasthan, India: a case report. *Journal of Parasitic Diseases*. 2010; 34: 94-96.
- Patnaik KC, Kapoor PN. Incidence and endemicity of guinea worm in India. *Indian Journal of Medical Research*. 1967; 55: 1231-42.
- Tiwari AK. Incidence and ecology of guinea worm disease in Rajasthan. *Rajasthan Medical Journal*. 1968; 8: 229-242.
- Barr M. The tail end of Guinea worm: Global eradication without a drug or vaccine. *The New England Journal of Medicine*. 2007; 356: 2561-2564.
- Choubisa SL. A brief and critical review on hydrofluorosis in diverse species of domestic animals in India. *Environmental Geochemistry and Health*. 2017; 40: 99-114.
- Choubisa SL. Fluoride Distribution in Drinking Groundwater in Rajasthan, India. *Current Science*. 2018; 114: 1851.
- Choubisa SL. Status of chronic fluoride exposure and its adverse health consequences in the tribal people of the scheduled area of Rajasthan, India. *Fluoride*. 2022; 55: 8-30.
- Spittle B. Out of the frying pan into the fire? : Guinea worm disease (*dracunculiasis*) and chronic fluorosis in the tribal people of the scheduled area of Rajasthan, India. (Editorial). *Fluoride*. 2022; 55: 1-7.
- Choubisa SL, Choubisa DK, Joshi SC, Choubisa L. Fluorosis in some tribal villages of Dungarpur district of Rajasthan, India. *Fluoride*. 1997; 30: 223-228.
- Choubisa SL. Endemic fluorosis in southern Rajasthan (India). *Fluoride*. 2001; 34: 61-70.
- Choubisa SL, Choubisa L, Choubisa DK. Endemic fluorosis in Rajasthan. *Indian Journal of Environmental Health*. 2001; 43: 177-189.
- Choubisa SL. A brief and critical review of hydrofluorosis in Rajasthan, India. *Fluoride*. 2018; 51: 13-33.
- Choubisa SL, Choubisa D. Genu-valgum (knock-knee) syndrome in fluorosis-endemic Rajasthan and its current status in India. *Fluoride*. 2019; 52: 161-168.
- Choubisa SL. Status of chronic fluoride exposure and its adverse health consequences in the tribal people of the scheduled area of Rajasthan, India. *Fluoride*. 2022; 55: 8-30.
- Choubisa SL, Choubisa D, Choubisa A. Fluoride contamination of groundwater and its threat to health of villagers and their domestic animals and agriculture crops in rural Rajasthan, India. *Environmental Geochemistry and Health*. 2022. doi.org/10.1007/s10653-022-01267-z.
- Choubisa SL. Some observations on endemic fluorosis in domestic animals of southern Rajasthan (India). *Veterinary Research Communications*. 1999; 23: 457-465.
- Choubisa SL. Chronic fluoride intoxication (fluorosis) in tribes and their domestic animals. *International Journal of Environmental Studies*. 1999; 56: 703-716.
- Choubisa SL. Fluoridated ground water and its toxic effects on domesticated animals residing in rural tribal areas of Rajasthan, India. *International Journal of Environmental Studies*. 2007; 64: 151-159.
- Choubisa SL. Osteo-dental fluorosis in horses and donkeys of Rajasthan, India. *Fluoride*. 2010; 43: 5-10.
- Choubisa SL. Fluorosis in dromedary camels of Rajasthan, India. *Fluoride*. 2010; 43: 194-199.
- Choubisa SL, Modasiya V, Bahura CK, Sheikh Z. Toxicity of fluoride in cattle of the Indian Thar Desert, Rajasthan, India. *Fluoride*. 2012; 45: 371-376.
- Choubisa SL. Fluoride toxicosis in immature herbivorous domestic animals living in low fluoride water endemic areas of Rajasthan, India: an observational survey. *Fluoride*. 2013; 46: 19-24.
- Choubisa SL. Fluorotoxicosis in diverse species of domestic animals inhabiting areas with high fluoride in drinking waters of Rajasthan, India. *Proceedings of the National Academy of Sciences, India Section B: Biological Sciences*. 2012; 83: 317-321.
- Choubisa SL, Mishra GV. Fluoride toxicosis in bovines and flocks of desert environment. *International Journal of Pharmacology and Biological Sciences*. 2013; 7: 35-40.
- Choubisa SL. A brief and critical review of chronic fluoride poisoning (fluorosis) in domesticated water buffaloes (*Bubalus bubalis*) in India: focus on its impact on rural economy. *Journal of Biomedical Research and Environmental Sciences*. 2022; 3: 096-104.