

Clinical Image

Primary Bilateral Anophtalmia

Hasnaoui Ihssan^{1*}; Berraho A²¹Department of Ophthalmologie B, Hospital of Specialities, CHU Ibn Sina Rabat, Morocco²Faculty of Medicine and Pharmacy, University Mohamed V, Rabat, Morocco***Corresponding author: Hasnaoui I**Ophthalmology B Departement , Faculty of Medicine and Pharmacy, University Mohamed V, Av. Abderrahim Bouabid, 10100 Rabat, Morocco.
Email: ihssanhasnaoui@gmail.com**Received:** July 14, 2023**Accepted:** August 29, 2023**Published:** September 05, 2023

Clinical Image

A 3 months old female child, who was born with bilateral anophtalmia after a normal full-term pregnancy by normal spontaneous vaginal delivery to a 32 years old mother, who had antenatal care in local health center. According to the mother, pregnancy went without any kind of complications. This was a third pregnancy from healthy parents with 2 healthy children. There was no history of congenital infections or any significant teratogenic drug intake during pregnancy. There was no history of fever, body rashes and no exposure to X-rays; and no family history of diabetes or any congenital pathology.

During ophthalmological examination the eyeballs were absent with eyelids deeply set, the free margins of the eyelids were adherent (Panel A). There was no associated dysmorphic facies. The diagnosis was confirmed with a Contrast-enhanced computed tomography of the orbit and brain. It revealed bilateral absence of the globes and optic nerves (Panel B). Chest X-ray, echocardiography and abdominal ultrasound scan were normal. Antibodies for Toxoplasma, Rubella and Cytomegalovirus were negative; she was taken up for bilateral, sequential orbital prosthesis implantation.

Author Statements

Conflicts of Interest

The authors have no conflicts of interest to declare.

Funding

We have any financial sources.

Consent

Written informed consent was obtained from the parent for publication of this case report and accompanying images. A copy of the written consent is available for review by the Editor-in-Chief of this journal on request.

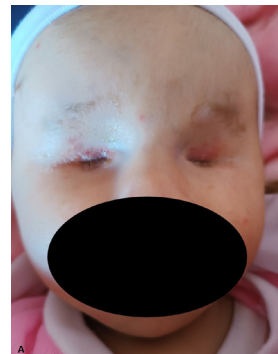

Figure A: Bilateral ankyloblepharon with palpebral collapse related to the absence of the eyeball.

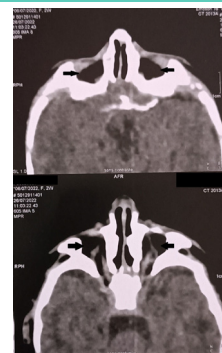


Figure B: Axial CECT image of orbit showing absent eyeballs, absent optic nerves and narrow orbital diameter.