

Review Article

Proliferative Verrucous Leukoplakia: An Update

Gante J^{1,2*}; Dubuc A^{1,2,4}; Laurencin-Dalcieux S^{1,3,4}; Cousty S^{1,2,5}

¹Division of General Dentistry, Health Campus, Paul Sabatier University, Toulouse, France

²Oral surgery Oral Medicine Department, CHU Toulouse, France

³Periodontology Department, CHU Toulouse, France

⁴CERPOP UMR 1295 INSERM, Paul Sabatier University, Toulouse, France

⁵LAPLACE UMR CNRS 5213, Paul Sabatier University, Toulouse, France

***Corresponding author: Gante J**

Oral Surgery Intern, Oral Medicine Department, CHU Toulouse Rangueil, 3 chemin des Maraîchers, 31 400 Toulouse, France.

Tel: + 33 6 86 35 84 09

Email: gantejulie@yahoo.fr

Received: September 25, 2023

Accepted: October 19, 2023

Published: October 26, 2023

Abstract

Objectives: Proliferative verrucous leukoplakia was first described by Hansen et al. in 1985. It is a rare form of oral leukoplakia with a high risk of malignant transformation.

A review of the scientific literature indicates that there is no consensus on the management and follow-up of proliferative verrucous leukoplakia.

This article aims to provide an update on the epidemiological, clinical, histological and immunohistochemical, diagnostic, treatment and follow-up data on the disease.

Materials and Methods: We performed a narrative review by searching the Pubmed and Google Scholar databases using keywords.

Results: 93 out of 446 selected articles were selected for analysis.

The majority of affected patients are women. The lesions are multifocal and usually occur on the gingiva and alveolar mucosa. The aetiology is idiopathic. The diagnosis is retrospective and based on the history of the disease. Apart from mapping the lesions using repeated biopsies to detect a malignant area progression, there is no recommended treatment to cure the disease.

Conclusion: The current understanding of this entity is based on the analysis of retrospective studies with weak scientific evidence. Expert recommendations regarding follow-up and management would facilitate better control of recurrence and malignant transformation rates.

Keywords: Multifocal verrucous leukoplakia ; Oral leukoplakia; Proliferative verrucous leukoplakia; Verrucous carcinoma

Introduction

Oral mucosal leukoplakia is a type of potentially malignant oral cavity lesion [1].

Among oral leukoplakias, there is a distinct pathological entity first described by Hansen et al. in 1985: proliferative verrucous leukoplakia (PVL), previously referred to as Oral Florid Papillomatosis (OFP) [2].

The lesions are slow growing, persistent and irreversible with a tendency to be multifocal and almost inevitably proliferate.

In addition to the lack of specific histopathological diagnostic criteria, the wide variety of morphological terminology used to describe the microscopic findings is subject to different interpretations, thus making its diagnosis difficult.

Diagnosis is usually retrospective and depends on the clinician's ability to recognise its progressive clinical-pathological stages, envisaged as a continuum of diseases from simple oral leukoplakia to squamous cell carcinoma after several years.

The malignant transformation rate is the highest of all potentially malignant lesions in the oral cavity [3].

A review of the scientific medical literature indicates that there is no consensus on the management and follow-up of this condition. The literature describes several treatments: from simple monitoring to invasive surgical treatment, laser excision or non-surgical treatments (medication, chemotherapy, phototherapy, radiotherapy) but there is no gold standard in terms of their efficacy.

In 2007, the World Health Organization (WHO) expert group proposed recommendations on precancerous lesions (1) and in 2020, the WHO updated this classification of potentially malignant lesions, still focused almost exclusively on their clinical features [4]. Despite the imperfection of the term PVL, the work-group recommended that it continued to be used.

In 2021, a new group of experts, from the American Academy of Oral and Maxillofacial Pathology (AAOMP) and the North American Society of Head and Neck Pathologists (NASHP), recommended the use of standardised histopathological criteria and appropriate descriptive terminology [5]. However, these criteria have not yet been widely evaluated, particularly in a clinical context.

The rationale for this work is the lack of national or international guidelines on the management of proliferative verrucous leukoplakia from the learned societies of dermatology, oral surgery or maxillofacial surgery.

The purpose of this article is to propose a narrative synthesis on PVL focusing on five themes: (1) epidemiology, (2) clinical, histology and immunohistochemistry, (3) diagnostics, (4) treatment and (5) follow-up.

Materials and Methods

Research Strategy

We performed the literature search by searching the MEDLINE database (Pubmed) and the Google Scholar search engine. The last search was conducted on February 13th 2023. The keywords entered were: proliferative, verrucous, multifocal, leukoplakia and leucoplakia.

The common limits of the queries were as follows:

- Only complete articles written in English and French were selected;
- The publication year of the articles ranged from September 1985 to January 2023;
- Only clinical trials, meta-analysis, systematic reviews, retrospective studies, cohort studies, case-control studies, descriptive epidemiological studies, and case series and case reports dealing exclusively with the treatment used were analysed;
- Case reports and series not dealing exclusively with the treatment used, articles dealing with potentially malignant lesions without mentioning separate data on PVL, letters to the editor, theses, updates or “mini-reviews” of the literature and citations were excluded.

Table 1: Summary of epidemiological characteristics of systematic reviews of PVL (X = data not available).

Author	Year of publication	Age (years)	Sex (%)	Localisation of lesions						Tobacco (%)	Alcohol (%)	HPV (%)
				Gingiva/Alveolar mucosa	Buccal mucosa	Tongue	Palate	Floor of mouth	Lip			
Abadie	2015	63,9	66,9	52	50,6					34,8		
Lafuente Ibanez de Mendoza	2021	> 60	67,4	57,8	44,8	32,9	22,4	12,1	7,4	39,3	23,2	
Palaia	2021	64,9	59,5							40,1	26,2	
Pentenero	2014	62	69,1	61,7/11,2	56,9	47,3	36,7	26,6	12,8	35,3	21	
Proano	2021	62,34	62,5	51,2	19,5	7,3	2,43	9,8	9,8	29,7	6,8	14,6
Ramos Garcia	2021	33-88	64,02	39,6	21,6					0-70	9,8-56	
Torrejon Moya	2020	67,4	67	50,9	44,9	40,6	Soft: 18,2	25,4	13,3	37	31,4	
Average		63,5	65,2							35,9		

The articles were selected based on the title and abstract and then on the availability of the full text. We also performed additional manual searches using the references of the selected articles.

Results

Screening of Studies

The research strategy yielded 446 publications and article abstracts. 329 were left after removing duplicates. At the end of this procedure, 93 articles were selected for analysis. The flow chart in Figure 1, created according to the PRISMA recommendations, summarises the selection process [6].

Epidemiology

Profile of affected patients (sex, age)

Patients suffering from PVL are over 60 years old (Table 1).

Most authors estimate a ratio of women to men of 4:1.

Ramos-Garcia et al. (7) and Abadie et al. (8) demonstrate no significant association between age, sex of patients and the rate of malignant lesion transformation.

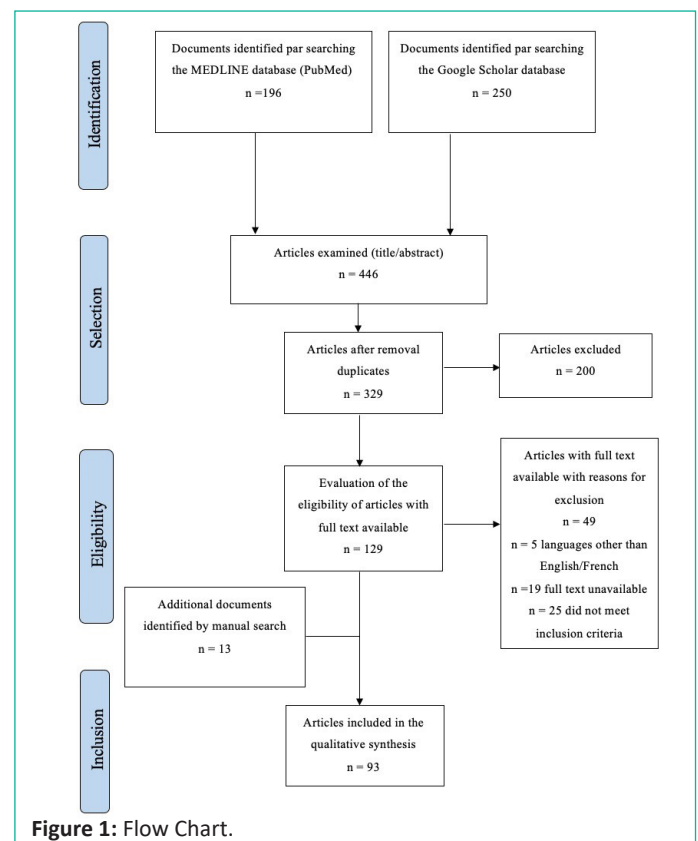


Figure 1: Flow Chart.




Figure 2: Histopathological continuum of PVL adapted from Hansen et al. and modified.

Conversely, Palaia et al. (9) found that women with PVL were 1.7 times more likely to experience malignant transformation and transformation to squamous cell carcinoma is estimated to be 3 times higher for women than for men.

Clinical Distribution of Lesions

The literature reports that PVL lesions are most commonly located in the gums and alveolar mucosa, followed by the jugal mucosa, the tongue, the palatal mucosa, the floor of the mouth and the lips.

Oral anatomical sites at high risk of malignant transformation are generally the tongue and floor of the mouth, whereas for PVL, it is the gingiva and jugal mucosa [10-12].

Carcinomas resulting from PVL are most likely to be located on the masticatory mucosa, particularly on the gingiva (squamous cell carcinomas) and on the hard palate (verrucous carcinomas) with a lower prevalence on the tongue (particularly the lateral border of the tongue).

There is a sub-type of PVL called gingival PVL, which occurs around the marginal gingiva of teeth and is particularly common in the anterior region.

The literature indicates that these lesions are multifocal in almost all patients. The number of lesions per patient differs in the retrospective studies: 8.2 for Zakrzewska et al. [13], 4.4 for Garcia-Chias et al. [14] and 2.6 for Silverman et al. [15]. This number is difficult to define for lesions involving the marginal gingiva of several adjacent teeth, the simplest way would be to consider them as non-contiguous sites [16].

The systematic review by Ramos Garcia et al. reports 1 to 17 leukoplakic lesions per patient [7].

Risk Factors (Smoking, Alcohol, Human papillomavirus)

Most authors mention smoking habits in their cohort but seem to exclude smoking as a risk factor for developing PVL.

Smoking doesn't seem to be involved in the carcinomatous transformation of PVL either.

Similarly to smoking, alcohol plays a major role in the carcinogenesis of the oral mucosa with a "dose-effect" relationship. Alcohol consumption combined with smoking increases the risk of cancer, particularly by promoting the passing of pro-carcinogenic substances through the mucosa or by activating cytochromes P450.

The few studies reporting alcohol consumption in their patients agree it should be excluded from the etiological factors for the occurrence of PVL.

Papillomaviruses are strictly human double-stranded circular DNA viruses belonging to the Papillomaviridae family. Most authors do not describe human papillomavirus as an aetiological factor in the development of PVL. However, it is difficult to draw conclusions due to the different detection methods, sensitivities and lack of control groups. There is a need for further studies that comply with standardised selection criteria and detection methods.

Clinical, Histology and Immunohistochemistry

Clinical

The abnormality of this lesion is its macroscopic variability according to its clinical stage and location. The different developmental stages of this disease can be observed at the same time, in the same patient and at different sites.

The lesions tend to go through 4 main clinical stages. In the initial stages, we see an isolated, homogeneous leukoplakia that is predominantly white or inhomogeneous, possibly with erythematous halo-like margins, thin or thick, with a smooth surface, non-protuberant, soft on palpation or verrucous and often asymptomatic. It does not disappear after removal of apparent traumatic causes, is persistent and does not detach when scraped.

Gradually, the lesions multiply and become thick, exophytic, papillomatous and/or verrucous and hard upon palpation [8,17].

Hansen et al. (2) describe PVL as a continuum of diseases ranging from simple hyperkeratosis to squamous cell carcinoma. The lesion may initially be classified at any point on the continuum, not develop further for an indefinite period of time, or progress more or less rapidly into a carcinoma.

They consider verrucous hyperplasia (VH) to be one of the intermediate stages of the disease. It was first described by Shear and Pindborg et al. [18].

However, the terminology "proliferative verrucous leukoplakia" and "proliferative verrucous hyperplasia" are not clinically or histologically interchangeable.

PVL should be seen as a clinical diagnosis while VH as a histological diagnosis.

First defined by Ackermann in 1948, Verrucous Carcinoma (VC) begins as a thin, well-defined white keratotic plaque that subsequently thickens and develops a papillomatous surface with rounded ends or verrucous surface with pointed ends. The lesion then becomes clinically indistinguishable from a verrucous carcinoma. Over time, new tumours appear, often with squamous cell carcinoma being the final stage. The exophytic proliferation of the verrucous carcinoma becomes endophytic and hard on palpation.

Verrucous carcinoma is considered a low-grade, slow-growing, well-differentiated tumour with extremely low metastatic potential. VH and VC can share overlapping histological and clinical features and are often indistinguishable.

Histology

There is no precise histological diagnosis for this lesion.

The high tendency for recurrence suggests that PVL is associated with diffuse microscopic changes within the oral mucosa, described as "field cancerisation".

Hansen et al. proposed a microscopic PVL classification scale from 0-10 where the main grades are: 0 = normal mucosa, 2=hyperkeratosis with little or no dysplasia, 4=verrucous hyperplasia, 6=verrucous carcinoma, 8=papillary squamous cell carcinoma and 10=poorly differentiated squamous cell carcinoma. The idea of there being a histological continuum is clear, with lesions slowly progressing to the higher grade, while regression to the lower stage is unusual.

Decades passed before Batsakis et al. [19] simplified this classification by removing the intermediate grades and retaining only 4 main grades: simple leukoplakia, verrucous hyperplasia, verrucous carcinoma and squamous cell carcinoma.

Figure II below, adapted from the Hansen et al. [2] continuum, summarises the clinical-histological data.

Immunohistochemistry

Studying immunological markers in potentially malignant lesions such as PVL could help to detect which lesions are likely to undergo malignant transformation when histology is not a contributing factor.

Studies showed high levels of some tumour growth and proliferation markers (P53 protein [20,21], Ki-67 antigen [20,22], minichromosome maintenance protein complex (MCM) [23,24]), aberrations in cell cycle regulatory genes with deletions, loss of heterozygosity and mutations (DNA ploidy [24-26]) or oral microbial diversity in some PVL samples [27]. Others found the presence of interleukin-6 [28], interleukin-5, interleukin1 β , transforming growth factor alpha [29], cell cycle regulatory genes p16INK4a and p14ARF [30], INSR + cancer-associated endothelial cells and ASPN+ [31].

However, no biomarker has yet met the reference criteria for risk stratification of malignant transformation in oral leukoplakia and PVL [32].

Even though there is an emerging body of evidence characterising the genomic and transcriptomic signature of PVL, this requires further research and should be investigated as part of an expert consensus proposal [33].

Also, artificial intelligence could be used in the future as an additional tool to support diagnosis [34].

Diagnosis

Various authors have proposed different diagnostic criteria: Hansen et al. [2]; Gandolfo et al. [11]; Ghazali et al. [35]; Cerero-Lapiedra et al. [36]; Carrard et al. [37]; Garcia-Chias et al. [14]; Ghosh et al. [38]; Garcia Pola et al. [39]; Villa et al. [40]; Thompson et al. [5]; Gonzalez-Moles et al. [41]; Lafuente Ibanez De Mendoza et al. [42]. Only the criteria set by Cerero-Lapiedra et al. [36] have been evaluated in retrospective studies [38,39].

In 2010, Cerero-Lapiedra et al. [37] proposed the following diagnostic criteria:

Major criteria:

- A. Lesion with at least 2 different sites in the oral cavity
- B. Presence of a verrucous area
- C. Changes in lesion size during the development of the disease
- D. Recurrence in a previously treated area

In terms of histopathology, it could be simple epithelial hyperkeratosis, verrucous hyperplasia, verrucous carcinoma or squamous cell carcinoma, *in situ* or infiltrating.

Minor criteria:

- A. An oral leukoplakia lesion occupying at least 3cm² when adding all areas together
- B. Female patient
- C. Non-smoking patient (male or female)
- D. Disease evolution longer than 5 years

The diagnosis of PVL is clearly established when:

- 3 major criteria are met (including criterion E)
- Or 2 major criteria (including E) and 2 minor criteria are met

Some forms of PVL can mimic Oral Lichen Planus (OLP) or Oral Lichenoid Lesions (OLL) [43-48].

The presence of striae and erythroplakia with multifocal white lesions may confuse the clinician. There is still debate surrounding whether a subset of PVLs can be presented as the evolution of an OLP or an OLL, or the continuum of the same potentially malignant lesion in a field cancerisation scenario.

Oral verrucous hyperplasia and verrucous carcinoma can be one of the intermediate stages of PVL but can also occur in isolation.

Therapeutic Management

There is currently no gold standard treatment for PVL. The available treatments essentially limit the progression of the disease without curing it. A distinction is made between surgical removals with a cold blade, surgical removal with a laser, local or systemic application of medicinal agents: retinoids, corticosteroids, methisoprinol, phototherapy, chemotherapy and radiotherapy. The latter two treatment options should only be used in the case of proven malignant lesions.

Surgical removal with a cold blade seeks to totally remove lesions, which is rarely possible given the multifocality of the lesions and the tissue loss that this procedure involves. Mapping with multiple and frequent biopsies is essential to detect areas where high-grade lesions may develop.

Even in the case of taking a simple biopsy, the choice of the area to be removed is tricky when the lesion is wide.

It has also been suggested that large mucosal lesions with mild to moderate dysplasia should be treated surgically [49].

This procedure may often require additional treatments, such as laser excision/vaporisation, advanced surgical treatments with tissue flaps or skin grafts that cannot guarantee eradication of the disease can at least allow for histological monitoring.

Despite high recurrence rates, surgery is unavoidable to histologically classify the disease and detect its malignant transformation as early as possible.

There is insufficient scientific evidence to conclude that any treatment strategy is capable of reducing PVL recurrence rates.

Follow-up

Malignant Transformation and Recurrence Rates

Recent systematic reviews were performed to determine the malignant transformation rate of PVL, Palaia et al. [9] (46.5%) and Lafuente Ibanez De Mendoza et al. [42] (65.8%).

These figures should be interpreted with caution as they are significantly influenced by the low methodological quality.

Iocca et al. [3] found a malignant transformation rate of 49.5% for PVL, the highest rate out of erythroleukoplakia, oral leukoplakia, oral submucosal fibrosis, oral lichenoid lesions and oral lichen planus. The annual malignant transformation rate of PVL is 9.3%, well above the above-mentioned potentially malignant lesions. These authors also demonstrated a significant negative correlation between the PVL transformation rate and the year of the published study (1985 to 2019). Therefore, it would be reasonable to assume that since the initial definition was proposed in 1985, more attention has been given to the condition and this has led to better management, which in turn allowed the rate of malignant transformation to be monitored over the years.

Proano et al. [50] investigated recurrence after treatment and estimated it at 67.2%. While we have a good understanding of the sites at high risk of recurrence, no correlation has yet been shown regarding the size or histological type of the lesion.

According to Palaia et al. [9] patients with PVL who progress to oral cavity cancer develop at least one second tumour at a different intraoral site in 46.5% of cases.

It has been estimated that the total number of malignant tumours varies from 1 to 14, and the average number of cancers per patient varies from 1.2 to 3.15 [7]. The time intervals to transformation fluctuate drastically between studies: from 1 to 210 months on average.

Studying 33 patients who had developed at least 2 SCCs resulting from a PVL, Bagan et al. demonstrated that the time to recurrence of a new malignant lesion decreased between each successive SCC (from 40.79 +/- 36.02 months from the first to the second cancer and from 16.67 +/- 12.01 from the fourth to the fifth cancer).

Squamous cell carcinoma resulting from PVL can be a distinct entity with smaller tumours and no regional or distant metastases. Patients who died after a long history of tumour recurrence had an average disease duration of 70 months compared to 7.75 months for those who died of conventional squamous cell carcinoma [12].

Meta-analysis conducted by Gonzales Moles et al. [41] revealed that 33.6% of patients with PVL developed verrucous carcinomas while 72.2% developed squamous cell carcinomas. These authors found that prolonged follow-up of patients after treatment is not associated with a higher mortality rate. Lastly, the mortality rate is not affected by the multiplicity of lesions.

Monitoring time Frame and Evaluation Methods

The majority of authors recommend regular follow-up every 6 months [51], every 3 to 6 months [50] or even every 2 months [49].

This follow-up should be both clinical (rigorous clinical examination, photography) and histological (biopsy mapping). Pho-

tographs and histological analysis should be compared at each follow-up to detect any macroscopic and microscopic changes in the lesions. Sharing photographs with pathologists is also encouraged [40,49].

It is important to establish objective evaluation criteria during follow-up, such as a specific disease score, or subjective criteria such as a pain and quality of life questionnaire. Educating the patient about self-examination of their lesions would help reduce the time to consultation in case of lesion changes.

Discussion

The current understanding of this entity is based on the analysis of retrospective studies with reported weak scientific evidence. Patient samples rarely exceed 50 patients with PVL, the largest cohort being Bagan et al. [10] with 63 patients.

According to Hansen's histopathological continuum, the diagnostic and treatment approach to the disease is known at the extreme stages of the disease, i.e. stages 2 (oral leukoplakia), 8 (papillary squamous cell carcinoma) and 10 (poorly differentiated squamous cell carcinoma).

Oral leukoplakia has been the subject of expert panel discussions, classification and grading, and treatment recommendations in the form of treatment decision trees [1,52,53].

Oral squamous cell carcinoma is subject to a strict pre-treatment assessment and an approved treatment based on the TNM (Tumour, Node, Metastasis) classification and validated in a Multidisciplinary Consultation Meeting (MCM).

However, in the intermediate stages of the disease, from 3 to 7 (grade 4: verrucous hyperplasia, grade 6: verrucous carcinoma), there is no consensus on either diagnostic or treatment. The line between VC as an intermediate stage of PVL and "primary" VC is difficult to draw but it seems important to make the distinction because of the difference in prognosis between both entities. Is this difference related to a real histological-morphological difference or to the treatment-resistant and recurrent nature of PVL?

Surgery is most commonly used to treat VCs either on its own or in combination with radiotherapy. Some authors treat VCs as SCCs (complete removal approach). Primary radiotherapy remains controversial. Even at an earlier histological stage of the continuum, should PVL be treated in the same way as "primary" VC, i.e. through conservative or complete removal surgery with wide, monobloc excision and macroscopic margins of 10 mm? There is no data available in the literature for PVL regarding the size of these margins. Could a systematic investigation into these margins play a key role in the recurrence of lesions?

Should all lesions be treated in the same way, even though they are at different histological stages, or should treatment be adapted to consider each lesion individually in the same patient?

Another problem is the multifocal nature of PVL from one anatomical site to another in the oral cavity. In these cases, the surgical treatment is substantial from a tissue removal point of view and can make post removal reconstruction difficult.

It is clear that, in view of the chronicity of such lesions, the diagnosis, the first-line treatment and the frequency of follow-up should be key points for consideration in MCM related to

this condition, which almost inevitably undergoes malignant transformation at present.

Conclusion

While PVL is better understood than when the original definition was proposed in 1985, it remains the potentially malignant oral cavity condition with the highest risk of malignant transformation. The current data in the literature helps clarify the epidemiology and to make a clinical and histological diagnosis, albeit retrospectively, of this condition. However, the lack of specific histological terminology means that many lesions potentially consistent with PVL are currently under-diagnosed.

Further research into its etiopathogenesis and immunohistochemical markers may facilitate early detection of carcinogenesis sites or anticipation of aggressive lesion behaviour.

In the absence of good practice recommendations for follow-up and treatment, recurrence rates and malignant transformation will remain difficult to control. This is the key issue with this condition, in which the line is particularly fine between verrucous or squamous cell carcinoma.

References

- Warnakulasuriya S, Johnson NW. Nomenclature and classification of potentially malignant disorders of the oral mucosa. *J Oral Pathol Med.* 2007; 36: 575-80.
- Hansen LS, Olson JA, Silverman S. Proliferative verrucous leukoplakia. A long-term study of thirty patients. *Oral Surg Oral Med Oral Pathol.* 1985; 60: 285-98.
- Iocca O, Sollecito TP, Alawi F, Weinstein GS, Newman JG, De Virgilio A, et al. Potentially malignant disorders of the oral cavity and oral dysplasia: A systematic review and meta-analysis of malignant transformation rate by subtype. *Head Neck.* 2020; 42: 539-55.
- Warnakulasuriya S, Kujan O, Aguirre-Urizar JM, Bagan JV, González-Moles MÁ, Kerr AR, et al. Oral potentially malignant disorders: A consensus report from an international seminar on nomenclature and classification, convened by the WHO Collaborating Centre for Oral Cancer. *Oral Dis.* 2021; 27: 1862-80.
- Thompson LDR, Fitzpatrick SG, Müller S, Eisenberg E, Upadhyaya JD, Lingen MW, et al. Proliferative verrucous leukoplakia: an expert consensus guideline for standardized assessment and reporting. *Head Neck Pathol.* 2021; 15: 572-87.
- Page MJ, McKenzie JE, Bossuyt PM, Boutron I, Hoffmann TC, Mulrow CD, et al. The PRISMA 2020 statement: an updated guideline for reporting systematic reviews. *BMJ.* 2021; 372: n71.
- Ramos-García P, González-Moles MÁ, Mello FW, Bagan JV, Warnakulasuriya S. Malignant transformation of oral proliferative verrucous leukoplakia: A systematic review and meta-analysis. *Oral Dis.* 2021; 27: 1896-907.
- Abadie WM, Partington EJ, Fowler CB, Schmalbach CE. Optimal management of proliferative verrucous leukoplakia: A systematic review of the literature. *Otolaryngol Head Neck Surg.* 2015; 153: 504-11.
- Palaia G, Bellisario A, Pampena R, Pippi R, Romeo U. Oral proliferative verrucous leukoplakia: progression to malignancy and clinical implications. Systematic review and meta-analysis. *Cancers.* 2021; 13: 4085.
- Bagan J, Murillo-Cortes J, Leopoldo-Rodado M, Sanchis-Bielsa JM, Bagan L. Oral cancer on the gingiva in patients with proliferative leukoplakia: A study of 30 cases. *J Periodontol.* 2019; 90: 1142-8.
- Gandolfo S, Castellani R, Pentenero M. Proliferative verrucous leukoplakia: A potentially malignant disorder involving periodontal sites. *J Periodontol.* 2009; 80: 274-81.
- Akrish S, Ben-Izhak O, Sabo E, Rachmiel A. Oral squamous cell carcinoma associated with proliferative verrucous leukoplakia compared with conventional squamous cell carcinoma—a clinical, histologic and immunohistochemical study. *Oral Surg Oral Med Oral Pathol Oral Radiol.* 2015; 119: 318-25.
- Zakrzewska JM, Lopes V, Speight P, Hopper C. Proliferative verrucous leukoplakia: a report of ten cases. *Oral Surg Oral Med Oral Pathol Oral Radiol Endod.* 1996; 82: 396-401.
- García-Chías B, Casado-De La Cruz L, Esparza-Gómez GC, Cerero-Lapiedra R. Diagnostic criteria in proliferative verrucous leukoplakia: evaluation. *Med Oral Patol Oral Cir Bucal.* 2014; 19: e335-9.
- Silverman S. Proliferative verrucous leukoplakia. *Oral Surg Oral Med Oral Pathol Oral Radiol Endodontol.* 1997; 84: 4.
- Upadhyaya JD, Fitzpatrick SG, Cohen DM, Bilodeau EA, Bhattacharyya I, Lewis JS, et al. Inter-observer variability in the diagnosis of proliferative verrucous leukoplakia: clinical implications for oral and maxillofacial surgeon understanding: A collaborative pilot study. *Head Neck Pathol.* 2020; 14: 156-65.
- Staines K, Rogers H. Oral leukoplakia and proliferative verrucous leukoplakia: a review for dental practitioners. *Br Dent J.* 2017; 223: 655-61.
- Shear M, Pindborg JJ, Odont D. Verrucous hyperplasia of the oral mucosa. *Cancer.* 1980; 46: 1855-62.
- Batsakis JG, Suarez P, El-Naggar AK. Proliferative verrucous leukoplakia and its related lesions. *Oral Oncol.* 1999; 35: 354-9.
- Rintala M, Vahlberg T, Salo T, Rautava J. Proliferative verrucous leukoplakia and its tumor markers: systematic review and meta-analysis. *Head Neck.* 2019; 41: 1499-507.
- Gopalakrishnan R, Weghorst CM, Lehman TA, Calvert RJ, Bijur G, Sabourin CL, et al. Mutated and wild-type p53 expression and HPV integration in proliferative verrucous leukoplakia and oral squamous cell carcinoma. *Oral Surg Oral Med Oral Pathol Oral Radiol Endod.* 1997; 83: 471-7.
- Fettig A, Pogrel MA, Silverman S, Bramanti TE, Da Costa M, Regezi JA. Proliferative verrucous leukoplakia of the gingiva. *Oral Surg Oral Med Oral Pathol Oral Radiol Endod.* 2000; 90: 723-30.
- Gouvêa AF, Vargas PA, Coletta RD, Jorge J, Lopes MA. Clinicopathological features and immunohistochemical expression of p53, Ki-67, Mcm-2 and Mcm-5 in proliferative verrucous leukoplakia. *J Oral Pathol Med.* 2010; 39: 447-52.
- Gouvêa AF, Santos Silva AR, Speight PM, Hunter K, Carlos R, Vargas PA, et al. High incidence of DNA ploidy abnormalities and increased Mcm2 expression may predict malignant change in oral proliferative verrucous leukoplakia. *Histopathology.* 2013; 62: 551-62.
- Kahn MA, Dockter ME, Hermann-Petrin JM. Proliferative verrucous leukoplakia. Four cases with flow cytometric analysis. *Oral Surg Oral Med Oral Pathol.* 1994; 78: 469-75.
- Klanrit P, Sperandio M, Brown AL, Shirlaw PJ, Challacombe SJ, Morgan PR, et al. DNA ploidy in proliferative verrucous leukoplakia. *Oral Oncol.* 2007; 43: 310-6.
- Herreros-Pomares A, Llorens C, Soriano B, Zhang F, Gallach S, Bagan L, et al. Oral microbiome in Proliferative verrucous Leukoplakia exhibits loss of diversity and enrichment of pathogens. *Oral Oncol.* 2021; 120: 105404.

28. Bagan L, Sáez GT, Tormos MC, Labaig-Rueda C, Murillo-Cortes J, Bagan JV. Salivary and serum interleukin-6 levels in proliferative verrucous leukoplakia. *Clin Oral Investig*. 2016; 20: 737-43.
29. Kannan R, Bijur GN, Mallery SR, Beck FM, Sabourin CLK, Jewell SD, et al. Transforming growth factor-alpha overexpression in proliferative verrucous leukoplakia and oral squamous cell carcinoma: an immunohistochemical study. *Oral Surg Oral Med Oral Pathol Oral Radiol Endod*. 1996; 82: 69-74.
30. Kresty LA, Mallery SR, Knobloch TJ, Li J, Lloyd M, Casto BC, et al. Frequent alterations of p16INK4a and p14ARF in oral proliferative verrucous leukoplakia. *Cancer Epidemiol Biomarkers Prev*. 2008; 17: 3179-87.
31. Akrish SJ, Rachmiel A, Sabo E, Vered M, Ben-Izhak O. Cancer-associated fibroblasts are an infrequent finding in the micro-environment of proliferative verrucous leukoplakia-associated squamous cell carcinoma. *J Oral Pathol Med*. 2017; 46: 353-8.
32. Celentano A, Glurich I, Borgnakke WS, Farah CS. World Workshop on Oral Medicine VII: prognostic biomarkers in oral leukoplakia and proliferative verrucous leukoplakia-A systematic review of retrospective studies. *Oral Dis*. 2021; 27: 848-80.
33. Farah CS. Molecular, genomic and mutational landscape of oral leukoplakia. *Oral Dis*. 2021; 27: 803-12.
34. Alshawwa SZ, Saleh A, Hasan M, Shah MA. Segmentation of Oral Leukoplakia (OL) and proliferative verrucous leukoplakia (PVL) using artificial intelligence techniques. *Rokaya D, éditeur. BioMed Res Int*. 2022; 2022: 1-11.
35. Ghazali N, Bakri MM, Zain RB. Aggressive, multifocal oral verrucous leukoplakia: proliferative verrucous leukoplakia or not?: aggressive. *J Oral Pathol Med*. 2003; 32: 383-92.
36. Cerero-Lapiedra R, Baladé-Martínez D, Moreno-López LA, Esparza-Gómez G, Bagán JV. Proliferative verrucous leukoplakia: A proposal for diagnostic criteria. *Med Oral Patol Oral Cir Bucal*. 2010; 15: e839-45.
37. Carrard VC, Brouns ER, van der Waal I. Proliferative verrucous leukoplakia; a critical appraisal of the diagnostic criteria. *Med Oral Patol Oral Cir Bucal*. 2013; 18: e411-3.
38. Ghosh S, Rao RS, Upadhyay MK, Kumari K, Sanketh DS, Raj AT, et al. Proliferative verrucous leukoplakia revisited: A retrospective clinicopathological study. *Clin Pract*. 2021; 11: 337-46.
39. Garcia-Pola MJ, Llorente-Pendás S, González-García M, García-Martín JM. The development of proliferative verrucous leukoplakia in oral lichen planus. A preliminary study. *Med Oral Patol Oral Cir Bucal*. 2016; 21: e328-34.
40. Villa A, Menon RS, Kerr AR, De Abreu Alves F, Guollo A, Ojeda D, et al. Proliferative leukoplakia: proposed new clinical diagnostic criteria. *Oral Dis*. 2018; 24: 749-60.
41. González-Moles MÁ, Ramos-García P, Warnakulasuriya S. A scoping review on gaps in the diagnostic criteria for proliferative verrucous leukoplakia: A conceptual proposal and diagnostic evidence-based criteria. *Cancers*. 2021; 13: 3669.
42. Lafuente Ibáñez de Mendoza I, Lorenzo Pouso AI, Aguirre Urizar JM, Barba Montero C, Blanco Carrión A, Gándara Vila P, et al. Malignant development of proliferative verrucous/multifocal leukoplakia: A critical systematic review, meta-analysis and proposal of diagnostic criteria. *J Oral Pathol Med*. 2022; 51: 30-8.
43. Morton TH, Cabay RJ, Epstein JB. Proliferative verrucous leukoplakia and its progression to oral carcinoma: report of three cases. *J Oral Pathol Med*. 2007; 36: 315-8.
44. Müller S. Oral epithelial dysplasia, atypical verrucous lesions and oral potentially malignant disorders: focus on histopathology. *Oral Surg Oral Med Oral Pathol Oral Radiol*. 2018; 125: 591-602.
45. Davidova LA, Fitzpatrick SG, Bhattacharyya I, Cohen DM, Islam MN. Lichenoid characteristics in premalignant verrucous lesions and verrucous carcinoma of the oral cavity. *Head Neck Pathol*. 2019; 13: 573-9.
46. McParland H, Warnakulasuriya S. Lichenoid morphology could be an early feature of oral proliferative verrucous leukoplakia. *J Oral Pathol Med*. 2021; 50: 229-35.
47. Gilligan G, Garola F, Piemonte E, Leonardi N, Panico R, Warnakulasuriya S. Lichenoid proliferative leukoplakia, lichenoid lesions with evolution to proliferative leukoplakia or a continuum of the same precancerous condition? A revised hypothesis. *J Oral Pathol Med*. 2021; 50: 129-35.
48. Thomson PJ, Goodson ML, Smith DR. Potentially malignant disorders revisited-The lichenoid lesion/proliferative verrucous leukoplakia conundrum. *J Oral Pathol Med*. 2018; 47: 557-65.
49. Favia G, Capodiferro S, Limongelli L, Tempesta A, Maiorano E. Malignant transformation of oral proliferative verrucous leukoplakia: a series of 48 patients with suggestions for management. *Int J Oral Maxillofac Surg*. 2021; 50: 14-20.
50. Proaño-Haro A, Bagan L, Bagan JV. Recurrences following treatment of proliferative verrucous leukoplakia: A systematic review and meta-analysis. *J Oral Pathol Med*. 2021; 50: 820-8.
51. Ottavioli A, Campana F, Catherine J-H, Massereau E, Del Grande J, Ordioni U. Leucoplasie verruqueuse proliférative: trois observations et revue de la littérature. *Ann Dermatol Venereol*. 2016; 143: 187-96.
52. van der Waal I. Potentially malignant disorders of the oral and oropharyngeal mucosa; terminology, classification and present concepts of management. *Oral Oncol*. 2009; 45: 317-23.
53. van der Waal I. Oral leukoplakia; a proposal for simplification and consistency of the clinical classification and terminology. *Med Oral Patol Oral Cir Bucal*. 2019; 24: e799-803.