

Case Report

Clinical Effect of Unani Medicine in a Case of Warts with Medical Images Before and After Treatment

Humaira Bano^{*}; Masroor Ali Qureshi

Colocation Research Center, RRIUM, JJ Hospital, India

***Corresponding author: Humaira Bano**

Colocation Research Center, RRIUM, Mumbai, JJ Hospital, Byculla, Mumbai-400008, India

Email: banu786.mau@gmail.com

Received: August 15, 2023**Accepted:** September 26, 2023**Published:** October 03, 2023**Abstract**

The Unani (Greek) system of medicine is one of the oldest forms of medicine used in various parts of the world. Despite its long journey, this medicine continues to thrive due to its vital role in the field of medical sciences. It encompasses comprehensive knowledge of the underlying causes and definitive treatments. In Unani Research OPDs, patients with chronic illnesses, especially those who have exhausted various integrative treatments, come seeking a cure. One such patient was a 33-year-old female who sought treatment for grainy growths on her fingers. She has prescribed a powder containing Mazu (*Quercus infectoria Oliv*), Murdar Sang (*Litharge*), Sandal (*Santalum album*), and kafoor (*Camphor*). After using this powder for 15 days, the patient experienced approximately 87.735% improvement. These results suggest that it could be a potential drug of choice for treating warts, deserving a large-scale clinical trial and the use of specialized scales to achieve even better and more significant results.

Keywords: Unani single medicines; Warts; Case study**Introduction**

Warts are grainy skin growths, sometimes pointed but may be oval and rounded shape, accompanied by itching and a stigma of disfigurement in the affected area. In the Unani medical terminology, this is referred to as *Masāmīr/Tha'ālīl*, derived from Arabic origin terminology used in the Unani System of medicine to describe a diseased condition of growth. Warts may appear whitish in colour, usually located within the skin, similar to a nail and this type of warts is called *Masāmīr*, if it has an irregular, projecting figure, is known as *Qarn* (horn). Warts are characterized by thick, phlegmatic, and sticky material due to certain causes [1]. The most common sites for warts are the fingers of the hands and soles [3]. In modern medicine, these are a dermatological condition caused by an infection with human papillomavirus (HPV) that is a DNA virus [4,5].

According to new researches its main treatment is destruction of the wart tissue or stimulation of cellular immunity against HPV. One category of treatment options is cytotoxic (freezing the skin cells) therapies, which involve the physical destruction of the wart tissue. Most of the time recurrence is occurs.

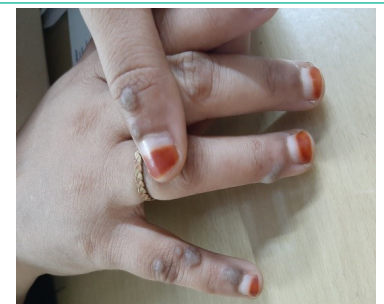

Case Study

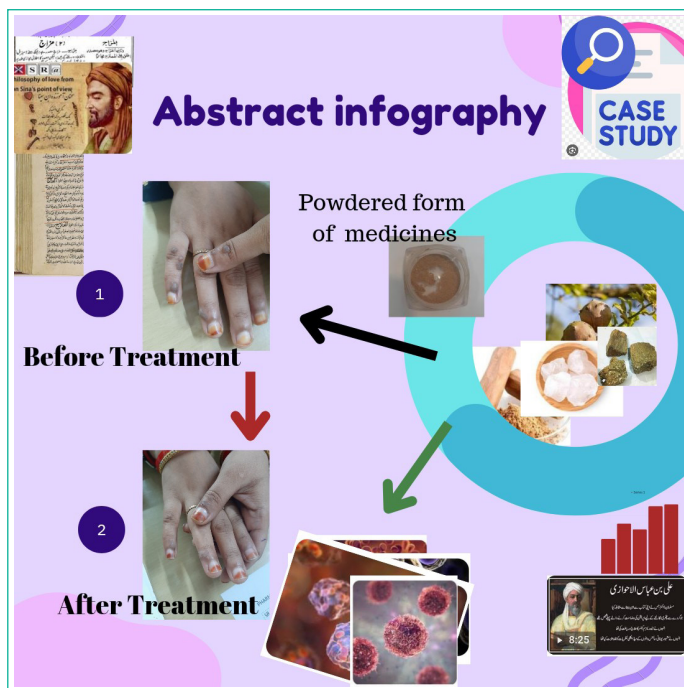
This case study has done in the OPD, with the consent of the patient have taken photographs before and after treatment. She was already informed to be written a case study and amend it in publication. For the purpose of treatment patient advised to get prepared mix powder of Mazu (*Quercus infectoria Oliv*)

1gm., Murdar Sang (*Litharge*) 1gm., Sandal (*Santalum album*) 3gm., and Kafoor (camphor) 0.5gm to be sprinkled over the warts for 15 days.

Objectives

To present a case study based on warts of the hands' fingers in a 33-year-old female patient with a safe, non-corrosive, approachable and non-invasive treatment and to conserve from surgical, chemical, and painful treatment method.

Before Treatment**After Treatment**



Method of Study

A 33-year-old female patient came to OPD at the colocation research Centre of the Unani Medicine J.J. hospital compound in Byculla Mumbai. The patient was suffered from multiple growths with pain, itching, and stigmatization disfigurement of hands. She sought various experts' consultations and got advice for surgery. She was apprehended of being increased in number or size might disfigure badly her hands. She visited the colocation Unani Research Center for a safe, and permanent solution. She was interrogated about her lifestyle and bowel habits, urination, even diet patterns and any allergic reactions. The examination has done thoroughly, with permission, photographs have taken, and she was prescribed to get prepared mix powder of Mazu (*Quercus infectoria Oliv*) 1gm., *Murdar Sang* (Litharge) 1gm., *Sandal* (*Santalum album*) 3gm. and *Kafoor* (camphor) 0.5gm to be sprinkled over the warts for 15 days [8-11].

Observation

Particulars of the Disease: listed in tabulated forms in two folds as quantitative and qualitative aspects.

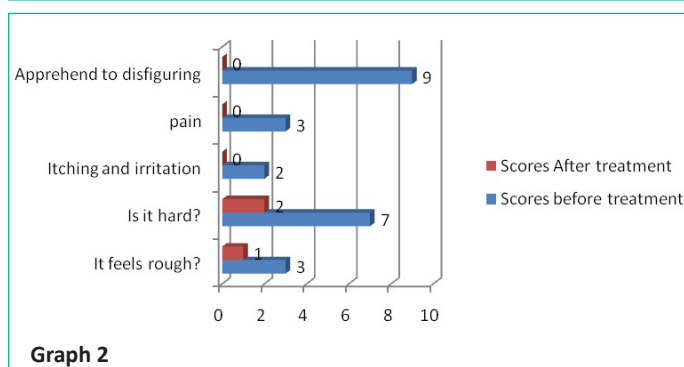
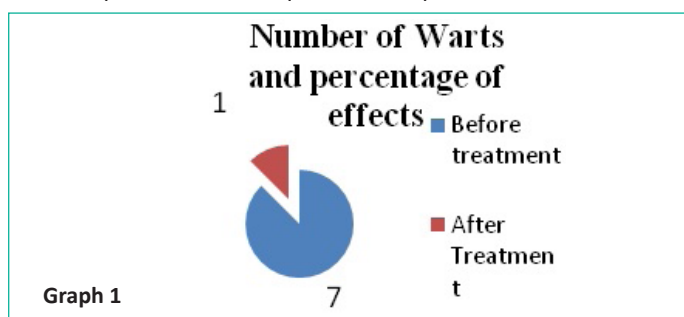


Table 1 shows a description of warts before and after treatment, with decreasing in numbers indicating the quantitative result of the warts after treatment. This result signifies the effectiveness of ingredients of the prepared powder as Ibn Sina mentioned the good effect of *Murdar Sang* (Litharge) in such types of skin growths [9]. Hakeem Najmulghani has reported the Mazu (*Quercus infectoria Oliv*) has tremendous effect in abnormal growth specially infected wound as it is astringent and dissolvent propertied proficiently [10].

Table 2 illustrates the scores before and after treatment in particulars of the patient. Before treatment, the patient experienced slight roughness over the warts having score of 3. However, in the last of the treatment there was a notable improvement, resulting in a score of 1.

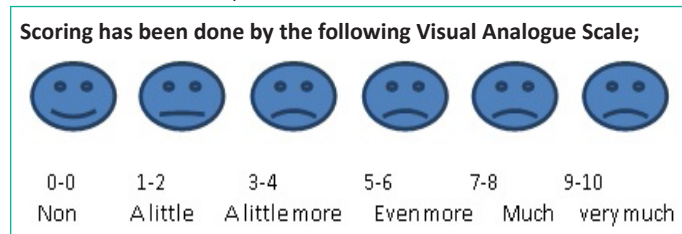
Table 1: Quantitative evaluation.

Particulars	Before treatment	After Treatment
Number of Warts	07	01
Percentage of effect		86%

Table 2: Qualitative evaluation.

S.No	Particulars with patient	Answers	Scores before treatment	Answers	Scores After treatment
1	It feels rough?	A little more	3	A little bit	1
2	Is it hard?	Much	7	A little more	2
3	Itching and irritation	A little bit	2	Non	0
4	pain	A little more	3	Non	0
5	Apprehend to disfiguring	Very much	9	Non	0
Total			24		3
			Result	87.5%	

Overall Quantitative and qualitative evaluation result is=87.735%



Additionally, the patient reported a significant degree of hardness before treatment, have score of 7. After treatment, there was a substantial improvement, although it remained somewhat hard, with a score of 2. Moreover before treatment the patient experienced a minor degree of itching and irritation, scoring 2. After treatment, there was a complete absence of itching and irritation, resulting in a score of 0.

Furthermore, the patient had slight pain in the warts, with a score of 3, which was alleviated entirely after treatment. Moreover, the patient expressed significant concern about potential disfigurement before treatment, scoring 9. However after treatment no disfigurement was observed, leading to a score of 0.

In total, the scores before treatment summed up to 24, indicating the overall severity of the symptoms. However, after treatment, the total score significantly decreased to 3, indicating a significant result of treatment and considerable improvement in the patient's condition.

Discussion

According to the research findings, the powdered form medicines stated above, which are sprinkled over the warts, exhibit great efficacy. As Murdar Sang (*Litharge*) has been mentioned to limit the skin growth and cleanse peculiar skin tissues [9]. Furthermore, Mazu (*Quercus infectoria Oliv*) has astringent and dissolving potentialities, which reduces the excessive growth of warts [10]. Henceforth, when mixed with Mazu (*Quercus infectoria Oliv*) and Murdar Sang (*Litharge*), Sandal (*Santalum album*) and Kafoor (*Camphor*) work as cooling and anti-infective agents. This one-of-a-kind mixture has demonstrated promising results in the treatment of warts.

Result

In the sum of the Overall Quantitative and qualitative evaluated result is=87.735% it is significantly high in the treatment. Result shows that this powdered medicine has also antiviral properties to combat them with potential strength.

Conclusion

The study concluded that Mazu (*Quercus infectoria Oliv*) Murdar Sang (*Litharge*) Sandal (*Santalum album*) and Kafoor (*Camphor*) in above said proportioned dust form is highly effective, gainful and safe in the treatment of warts, there are no more complaints noted and no more growth of warts appeared, patient Was happy and with no more apprehension of future growing such growth on her hands. Hence, patient visited to follow-up and after two months she got completely relief with no any recurrence or other problems.

Author Statements

Disclaimer

This work is original, photographs has been taken with permission of the patient to publish as a case study.

Conflict of Interest

There is no conflict of interest between the authors.

References

1. Bano H. An illustration of clinical warts before and after treatment with the Una ni kit medicines in general OPD: A case study. *J Clin Med Img. Case Rep.* 2023; 3: 1488.
2. Ibn-Al-Quff A. daula Abul-furj ibnul quff Al-Masihi. *Kitab-Al-Umdah fil jarahat Urdu Central Council Research in Unani Medicine Ministry of Health and Family welfare Govt. of India New Delhi.* 1896; 1: 177.
3. Ismail JM, Zakheera-e-Khwarzam T. Shahi. Lucknow Kishore MN, translator. 1903; 7: 37.
4. Singh Y. The application of machine learning in predicting outcome of cryotherapy and immunotherapy for wart removal. *Ann Dermatol.* 2021; 33: 345-50.
5. Quinlan JD. Human papillomavirus: screening, testing, and prevention. *Am Fam Physician.* 2021; 104: 152-159.
6. Kabiruddin MB. e-kabeer Hikmat book depot Hyderabad Dakin. Urdu. 1935; 1: 42.
7. Tabrī AHABM. "Al-MūālījatBūqratīyaurdu" CCRUM. New Delhi: Ministry of Health and family welfare Govt. of India. 1997; 215.
8. Ibn Sina, Abdullah AAHb. *Alqanoon fil tib.* Tranlatesd by Gulam Hasnain Kanturi. Munshi Naval Kishore Lucknow. 1896; 2: 145.
9. Najmulghani HM. *Khaza-i-nul Advia.* CCRUM. New Delhi: Ministry of Health and family welfare Govt. of India. 2010; 6 205.
10. Al Quff I. *Aminaadaula Abul furj Al Masihi. Kitab Umdah FI-Jarahat CCRUM.* 1986; 1: 292.