

## Case Report

# Behind the Eye: Exploring the Threat of Subconjunctival Cysticercosis

Hala Elbelidi\*, Baiz Taha; Yahya Saoiabi; Lalla Ouafa Cherkaoui

Department of Ophthalmology A, Specialty Hospital, Rabat, Morocco

\*Corresponding author: Hala Elbelidi

Department of Ophthalmology A, Specialty Hospital, Rabat, Morocco.

Email: dr.elbelidi.hala@gmail.com

Received: February 20, 2023

Accepted: March 28, 2023

Published: April 04, 2023

## Abstract

This report presents a rare case of a 25-year-old man with a *Taenia solium* worm found under the conjunctiva of his left eye. The patient had experienced redness, pain, itching, and epiphora in the affected eye. Subsequent examination revealed conjunctival congestion and a moving whitish linear formation, which was diagnosed as subconjunctival ocular parasitosis. The patient underwent successful surgical removal of the parasite and recovered without complications. The report highlights the importance of early diagnosis and prompt treatment to prevent permanent vision loss in cases of ocular parasitosis.

**Keywords:** Ocular parasitosis; *Taenia solium*; Cysticercosis; Subconjunctival

## Introduction

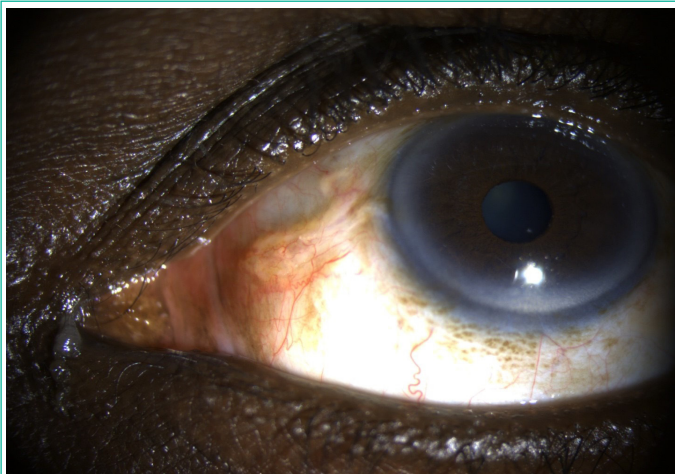
Ocular parasitosis has been a source of interest for ophthalmologists due to the diverse ways it manifests [1]. While ocular involvement is not crucial to the parasite's life cycle, the discovery of intraocular parasites is uncommon and is typically caused by abnormal parasite tissue migration. Ocular pathology can result from either direct invasion and tissue migration of parasite larvae or adults or indirectly from toxic and/or immune-mediated reactions [2].

Cysticercosis is a parasitic infection caused by the cystic form of *taenia solium* or *taenia saginata* larvae in human tissue [3]. It spreads through the fecal-oral route, often through contaminated water or food [4]. While adult worms primarily cause intestinal obstruction and malnutrition, larvae can produce more serious conditions, including subcutaneous tissue, muscle, and central nervous system invasion [3]. Ocular structures are affected in 13-46% of infected individuals, and ocular manifestations can be severe, resulting in blindness lasting 3-5 years due to the release of toxic products from the growing or dying cysticercosis [5].

## Case Report

This report details an incredibly rare case of a *Taenia solium* worm discovered under the conjunctiva in a 25-year-old man living in a rural area. The patient presented to the ophthalmol-

ogy emergency room with redness and pain in the left eye for 7 days, along with itching and epiphora. The episode was not linked to decreased visual acuity, and the patient had no history of ocular trauma, prior similar occurrences, or use of topical medications. The rest of the patient's medical history was unremarkable. Uncorrected visual acuity was 0.1 LogMAR in both eyes, and intraocular pressure was normal. Examination of the left eye revealed conjunctival congestion and a moving whitish linear formation in the nasal region below the bulbar conjunctiva (Figure 1), while the examination of the right eye was normal. The diagnosis was subconjunctival ocular parasitosis, and further tests, including cardiac ultrasound, abdominal ultrasound, and chest X-ray, produced normal results. Routine blood counts were unremarkable, and Enzyme-Linked Immunosorbent Assay (ELISA) for the detection of antibody to cysticercosis was negative. Stool examination, on the other hand, revealed *Taenia solium* ova. Magnetic resonance imaging of the brain and orbit showed cysticercosis cyst in the left eye. Surgical extraction of the parasite resulted in the removal of a white, translucent parasite measuring approximately 15mm in length and 0.6mm in diameter. After undergoing surgery to remove the worm and parasitological examination, the patient was treated with anthelmintic medication. The surgical and post-surgical course was favorable.



**Figure 1:** Clinical picture of the affected eye. Note the conjunctival congestion and the whitish linear formation in the nasal region below the bulbar conjunctiva.

### Discussion

Taeniasis, caused by infection with *Taenia solium* in adults, is prevalent worldwide but is endemic in some regions [6]. Although cysticercosis is rare in people who do not consume pork. Inflammation in ocular tissue is typically very severe in parasitic infections, often accompanied by pain and redness. Identification and management of such cases can be aided by stool examination, high-resolution ultrasonography, computed tomography, and magnetic resonance imaging [7].

The removal of the parasite through surgery is the preferred treatment for live cases, given the risk of migration in mobile worms [8]. However, it is important to note that dead parasites may not elicit any inflammation and may be well-managed through observation. And if surgical removal is deemed necessary, care must be taken not to disrupt the capsule or the outer coating of these worms, which may trigger an anaphylaxis-like reaction. In cases of intraocular parasitosis, it is typically recommended to treat the condition systemically with antihelminthic medication and steroids.

In addition to cysticercosis, other parasitic infections that can affect the eye include toxocariasis, onchocerciasis, and loiasis, among others [1]. These infections can also result in severe ocular pathology and may require prompt and appropriate treatment to prevent vision loss.

Prevention of ocular parasitosis can be achieved through basic hygiene measures, such as washing hands before eating, proper cooking of meat, and avoiding consumption of contaminated water [9]. Health education and awareness campaigns are also important to inform the public about the risks and ways to prevent infection.

### Conclusion

Ocular parasitosis is a rare but fascinating condition that can result in severe ocular pathology and even blindness. Early diagnosis and prompt treatment, including surgical removal of the parasite, is crucial to prevent permanent vision loss. Prevention measures, such as basic hygiene practices, can also play an important role in reducing the incidence of these infections.

### References

1. Ament CS, Young LH. Ocular manifestations of helminthic infections: onchocerciasis, cysticercosis, toxocariasis, and diffuse unilateral subacute neuroretinitis. *International Ophthalmology Clinics*. 2006; 46: 1–10.
2. Padhi TR, Das S, Sharma S, Rath S, Tripathy D, et al. Ocular parasitoses: a comprehensive review. *Surv Ophthalmol*. 2017; 62: 161–189.
3. Garcia HH, Gonzalez AE, Evans CAW, Gilman RH. *Taenia solium* cysticercosis. *The Lancet*. 2003; 362: 547–556.
4. Del Brutto OH, Sotelo J, Roman G. *Neurocysticercosis: A Clinical Handbook*. Lisse, The Netherlands: Swets & Zeitlinger; 1998.
5. Dhiman R, Devi S, Duraipandi K, Chandra P, Tandon R, et al. Cysticercosis of the eye. *International Journal of Ophthalmology*. 2017; 10: 1319–1324.
6. Zammarchi L, Strohmeier M, Bartalesi F, Bruno E, Munoz J, et al. Epidemiology and management of cysticercosis and *Taenia solium* taeniasis in Europe, systematic review 1990-2011. *PLoS One*. 2013; 8: e69537.
7. Nimir AR, Saliem A, Ibrahim IA. Ophthalmic parasitosis: a review article. *Interdisciplinary Perspectives on Infectious Diseases*. 2012; 2012: 587402.
8. Sah R, Khatri A, Kharel R, Kc H, Rabaan AA, et al. Case report: management of dead intraocular helminth parasites in asymptomatic patients. *The American Journal of Tropical Medicine and Hygiene*. 2020; 103: 719–722.
9. Del Brutto OH, Sotelo J, Roman G. *Neurocysticercosis: A Clinical Handbook*. Lisse, The Netherlands: Swets & Zeitlinger; 1998.